

Sutures and Suturing

Goals

A surgical suture is one that approximates the adjacent cut surfaces or compresses blood vessels to stop bleeding. Suturing is performed to

1. Provide an adequate tension of wound closure without dead space but loose enough to obviate tissue ischemia and necrosis
2. Maintain hemostasis
3. Permit primary-intention healing
4. Provide support for tissue margins until they have healed and the support is no longer needed
5. Reduce postoperative pain
6. Prevent bone exposure resulting in delayed healing and unnecessary resorption
7. Permit proper flap position

Suture Material

Surgical sutures have been used to close wounds since prehistoric times (50,000–30,000 BC) gave us the first written description of their use dating back as early as 4,000 BC (Macht and Krizek, 1978). Many materials have been used throughout the centuries, such as gold, silver, hemp, fascia, hair, linen, and bark. Yet none have provided all of the desired characteristics.

Qualities of the Ideal Suture Material

The following qualities of the ideal suture material are compiled from Postlethwait (1971), Varma and colleagues (1974), and Ethicon (1985):

1. Pliability, for ease of handling
2. Knot security
3. Sterilizability
4. Appropriate elasticity
5. Nonreactivity
6. Adequate tensile strength for wound healing
7. Chemical biodegradability as opposed to foreign body breakdown

With the possible exception of coated Vicryl (Ethicon, Somerville, New Jersey), none of the sutures available today meet these criteria. Table 3-1 lists the various materials—natural, synthetic, absorbable (digested by body enzymes or hydrolyzed), and nonabsorbable—available for periodontal use.

Use

1. Silk and synthetic sutures are employed most often.
2. Gut sutures are used only when retrieval is difficult when securing grafts and in younger patients. The limited physical characteristics of gut sutures do not warrant their routine use.
3. When using gut (plain or chromic) sutures, it is often advantageous to soak the package in warm water for a half-hour and to pull gently but firmly on the suture when opened. This will remove the kinks and straighten the suture. Finally, lubricating the suture lightly with petrolatum or sterile bone wax will prevent brittleness. **Note: This is not necessary with Ethicon sutures.**
4. Monofilament sutures are recommended for bone augmentation procedures to prevent “wicking,” reduce the inflammatory response, and permit longer retention (10–14 days).
5. Gore-Tex (Flagstaff, Arizona) and coated Vicryl sutures are recommended for guided tissue regeneration procedures.

Material Choice

The choice of materials depends on the following:

1. Surgical Procedure
 - a. Plastic procedures

Suture Site	4-0 to 6-0
Needle Size	P-3*
Material	Chromic gut, silk, monofilament
 - b. Regeneration

Suture Site	3-0 to 5-0
Needle Size	P-3; RT-16†
Material	Gore-Tex, Vicryl
 - c. Apically positioned flaps

Suture Site	4-0
Needle Size	J-1; FS2; P-3
Material	silk

*Small needles (P-3) are more difficult to negotiate the posterior interproximal areas.

†Gore-Tex.

- d. Periosteal suturing

Suture Site	4-0 or 5-0
Needle Size	J-1; P-3
Material	silk
- e. Extractions

Suture Site	3-0 or 4-0
Needle Size	FS-2; X-1
Material	silk

2. Biocompatibility‡
3. Clinical experience and preference
4. Quality and thickness of tissue
5. Rate of absorption versus time for tissue healing

Table 3-2 outlines the characteristics and applications of resorbable and nonresorbable sutures.

Note: Because silk is a multifilament material that “wicks,” it is not the material of choice when any sterile materials are used (eg, implants, bone grafts, guided tissue regeneration, or guided bone regeneration) or in the presence of infection (Silverstein and Kurtzman, 2005). The ideal material for these procedures is expanded polytetrafluoroethylene (ePTFE).

Knots and Knot Tying

“Suture security is the ability of the knot and material to maintain tissue approximation during the healing process” (Thacker and colleagues, 1975). Failure is generally the result of untying owing to knot slippage or breakage. Since the knot strength is always less than the tensile strength of the material, when force is applied, the site of disruption is always the knot (Worsfield, 1961; Thacker and colleagues, 1975). This is because shear forces produced in the knot lead to breakage.

Knot slippage or security is a function of the coefficient of friction within the knot (Price, 1948; Hermann, 1971). This is determined by the nature of the material, suture diameter, and type of knot. Monofilament and coated sutures (Teflon, silicon) have a low coefficient of friction and a high degree of slippage; braided and twisted sutures such as uncoated Dacron and catgut

‡These recommendations are not for microsurgical procedures.

Table 3-1 Sutures and Suturing

Suture	Types	Raw Material	Absorption	Suture Tensile Strength	Tissue Reaction	Knot Tensile Strength	Indications	Ease of Handling
Surgical gut	Plain	Collagen from healthy mammals	Digested by body enzymes within 70 d	+ (least)	Moderate ++++	+++	Rapidly healing mucosa Avoid suture removal	Absorbable; should not be used where extended approximation of tissues under stress is required Should not be used in patients with known sensitivities or allergies to collagen or chromium
Surgical gut	Chromic	Collagen from healthy mammals treated with chromic salts	Digested by body enzymes within 90 d	+	Moderate but less than plain gut ++++	+++	As above; slower absorption	
Coated Vicryl (polyglactin 910)	Braided Coated	Copolymer of lactide and glycolide coated with polyglactin 370 and calcium stearate	Hydrolysis 56–70 d	+++	Mild ++	++	Subepithelial mucosal surfaces Vessel ligation All types of general closure	+++
Dexon (polyglycolic acid)	Braided Coated	Homopolymer of glycolic acid coated with polaxamer 188	Slow hydrolysis after 60–90 d	+++	Mild ++	++	Subepithelial sutures Mucosal surfaces	++++
PDS (polydioxanone)	Monofilament Braided	Polyester polymer	Slow hydrolysis 180–210 d	++++	Slight +	++	Vessel ligation Absorbable suture with extended wound support	++
Surgical silk	Monofilament Braided	Natural protein fiber of raw silk treated with silicon protein or wax	Usually cannot be found after 2 yr	++	Moderate ++++	+	Mucosal surfaces	++++ Should not be used in patients with known sensitivities or allergies to silk
Nylon Duralon Ethilon	Monofilament	Long-chain aliphatic polymers Nylon 6 or nylon 6.6	Degrades at a rate of 15–20%/yr	+++	Extremely low 0-+	++	Skin closure	++
Nylon Duralon Suegilon	Braided	Polyamide polymer	Degrades at a rate of 15–20%/yr	+++	Extremely low 0-+	++	Skin closure Mucosal surfaces	++++
Polyester Mersilene Dacron Ethibond	Braided	Polyester, Polyethylene, Terephthalate coated with polybutylate	Nonabsorbable	+++	Minimal +	+++	Cardiovascular, plastic, general surgery	+++ None known
Peolene (polypropylene)	Monofilament	Polymer of propylene	Nonabsorbable	+++	Minimal+ transient acute reaction	++	General, plastic, cardiovascular, skin surgery	++
Gore-Tex	Monofilament	Expanded polytetrafluoroethylene (ePTFE)	Nonabsorbable	+++	Extremely low	++	All types of soft tissue approximation and cardiovascular surgery	++++ Not known
Monocryl (poliglecaprone 25)	Monofilament	Poliglecaprone 25 Copolymer of glycolide and caprolactone	Hydrolysis 90–120 d	++++	Minimal +	+++	Soft tissue closure	+++ Absorbable; should not be used where extended approximation of tissues under stress is required

Table 3-2 Characteristics and Applications of Resorbable and Nonresorbable Sutures

Suture Technique	Discipline Used	Tensile Strength Requirements	Type of Needle Recommended	Diameter of Material Recommended	Type of Material Recommended	Recommended Knot	General and Specific Situations Used
Interrupted suture	Periodontology, dental implant and oral surgery	Minimal to moderate	$\frac{3}{8}$ reverse cutting, tapered	4-0	Chromic gut, silk (PTFE)	Slip knot	Interproximal suturing
Figure eight suture	Periodontology and dental implant surgery, extraction sites	Minimal to moderate	$\frac{1}{2}$ or $\frac{5}{8}$ reverse cutting, tapered	4-0	Polyester "color" braided, polypropylene, monofilament nylon	Surgeon's knot	Flaps not under tension
Sling suture	Periodontology, dental implant and oral surgery	Moderate	Taper-cut	5-0	Chromic gut, gut	Slip knot*	Primary lingual of mandibular molar region
Horizontal mattress suture	Dental implant and oral surgery	High	$\frac{3}{8}$ reverse cutting, taper-cut	5-0	Polyester "color" braided, polypropylene, monofilament nylon	Surgeon's knot	
Vertical mattress suture				4-0	Chromic gut, gut, silk, PTFE	Slip knot	Used when a flap has been elevated on only one side
				3-0	Polyglycolic acid (PGA)	Surgeon's knot	Used in anterior mandible or posterior region to resist muscle pull
				4-0	Chromic, gut, silk	Slip knot	Used to resist muscle pull, closely adapt flaps to bone and either teeth or dental implants
				3-0	PGA	Surgeon's knot	Can also be used to apically or coronally position flaps
				3-0	Silk	Slip knot	Used to resist muscle pull, closely adapt flaps to bone and either teeth or dental implants
				3-0	PGA	Surgeon's knot	Can also be used to apically or coronally position flaps
Vertical sling mattress suture	Periodontology, dental implant and oral surgery, especially when performing guided tissue and bone regenerative techniques	High	$\frac{3}{8}$ reverse cutting, taper-cut	3-0	PGA	Surgeon's knot	Used to resist muscle pull, closely adapt flaps to bone, regenerative barriers, and dental implants, along with maintaining approximation of flap edges
Continuous independent sling suture	Periodontology, dental implant and oral surgery	High	$\frac{3}{8}$ reverse cutting, taper-cut	3-0	Silk	Slip knot	Used to resist muscle pull, closely adapt flaps to bone, regenerative barriers, and dental implants, along with maintaining approximation of flap edges
				4-0	PGA	Surgeon's knot	Used primarily in edentulous areas such as mandibular anterior or posterior region to resist muscle pull
				4-0	Silk	Slip knot	Used often in dental implant and bone augmentation procedures and in hyperplastic/fibrous ridge reduction for denture stability

*Restricted areas such as buccal vestibule maxillary molars or mucogingival surgery (eg, soft tissue grafts). (Silverstein L, 1999)

have greater knot security because of their high coefficient of friction (Taylor, 1938).

It is interesting to note that basic suture silk, although extremely user friendly, is distinctly inferior in terms of strength and knot security compared with other materials (Hermann, 1971). It also shows a high degree of tissue reaction (Postlethwait, 1968; Taylor, 1978), and the addition of wax or silicon to reduce the tissue reaction and prevent wicking further diminishes knot security (Hermann, 1971).

Knot selection is the last of the variables and the one over which surgeons have the most influence. Knot security has been found to vary greatly among clinicians, and even the security of knots tied by the same clinician varies at different times (Hermann, 1971).

A sutured knot has three components (Figure 3-1) (Thacker and colleagues, 1975):

1. The *loop* created by the knot (Figure 3-1A)
2. The *knot* itself, which is composed of a number of tight “throws” (Figure 3-1B); each throw represents a weave of the two strands
3. The *ears*, which are the cut ends of the suture

In Figure 3-2, we see the four knots most commonly used in periodontal surgery. In a study, Thacker (1975) found that the granny knot was the least secure, always requiring more throws or ties to achieve the same knot strength as the square or surgical knot. For materials with a high degree of slippage (monofilament or coated sutures), flat and square throws were recommended, with *all additional throws being squared*. Cutting the ears of the suture too short is contraindicated when slippage is great because the knot will come untied if the slippage exceeds the length of the ears. Loosely tied knots were shown to have the highest degree of slippage, whereas in tight knots, slippage was not a significant factor.

Principles of Suturing

Ethicon (1985) recommends the following principles for knot tying:

1. The completed knot must be tight, firm, and tied so that slippage will not occur.
2. To avoid *wicking of bacteria*, knots should not be placed in incision lines.
3. Knots should be small and the ends cut short (2–3 mm).
4. Avoid excessive tension to finer-gauge materials because breakage may occur.
5. Avoid using a jerking motion, which may break the suture.
6. Avoid crushing or crimping of suture materials by not using hemostats or needle holders on them except on the free end for tying.
7. Do not tie the suture too tightly because tissue necrosis may occur. Knot tension should not produce tissue blanching.

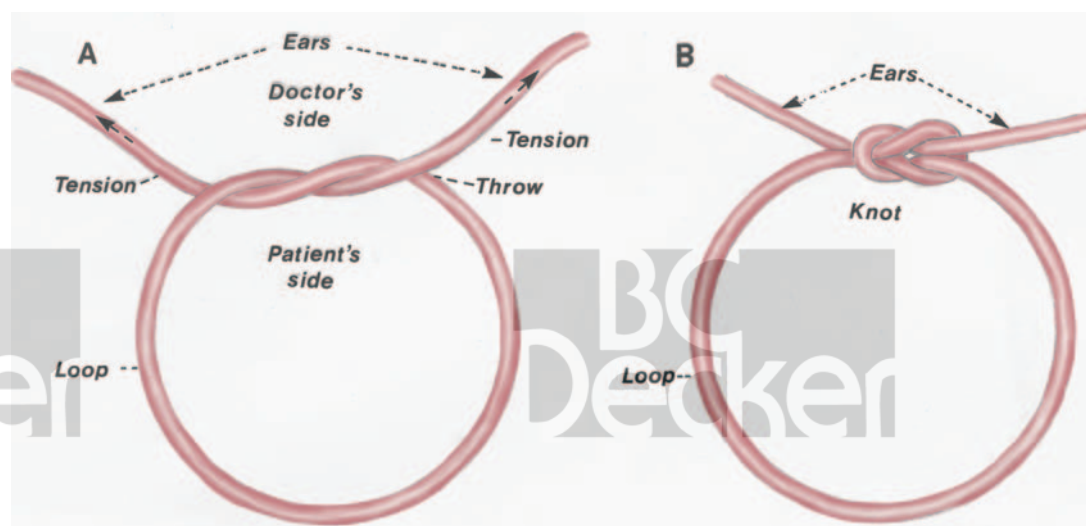


FIGURE 3-1. Knot anatomy. A, Various knot components prior to completion. B, Completed knot anatomy.

8. Maintain adequate traction on one end while tying to avoid loosening the first loop.
9. The surgeons knot and square knot strength, although generally not needing more than two throws, will have increased strength with an additional throw.
10. Granny knots and coated and monofilament sutures require additional throws for knot security and to prevent slippage. Coated Vicryl will hold with four throws—two full square knots.

Sutures should be removed as atraumatically and cleanly as possible. Ethicon (1985) recom-

mends the following principles for suture removal:

1. The area should be swabbed with hydrogen peroxide for removal of encrusted necrotic debris, blood, and serum from about the sutures.
2. A sharp suture scissors should be used to cut the loops of individual or continuous sutures about the teeth. It is often helpful to use a no. 23 explorer to help lift the sutures if they are within the sulcus or in close opposition to the tissue. This will avoid tissue damage and unnecessary pain.

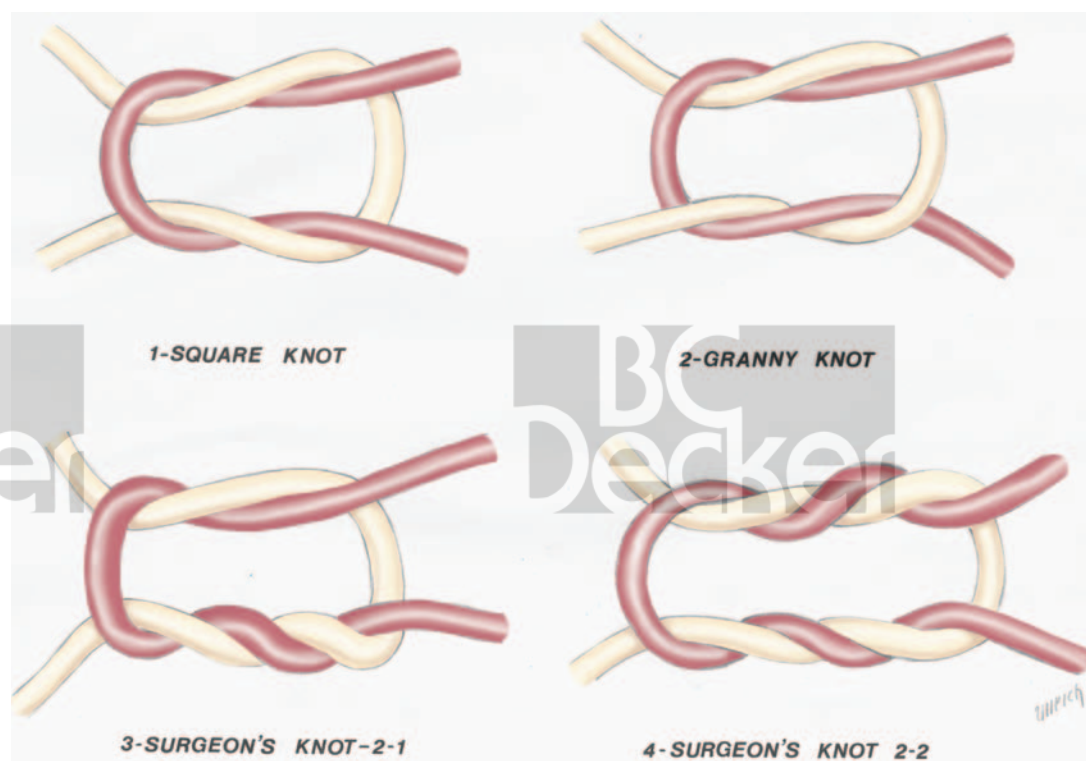


FIGURE 3-2. Suturing knots.

3. A cotton pliers is now used to remove the sutures. The location of the knots should be noted so that they can be removed first. This will prevent unnecessary entrapment under the flap.

Note: Sutures should be removed in 7 to 10 days to prevent epithelialization or wicking about the suture.

Surgical Needles

Most surgical needles are fabricated from heat-treated steel and possess a microsilicon finish to diminish tissue drag and a tip that is extremely sharp and has undergone electropolishing (Ethicon, 1985). The surgical needle has a basic design composed of three parts (Figure 3-3):

1. The eye which is press-fitted or swaged (eyeless) permits the suture and needle to act as a single unit to decrease trauma.
2. The *body* which is the widest point of needle and is also referred to as *the grasping area*. The body comes in a number of shapes (round, oval, rectangular, trapezoid, or side flattened).
3. The point which runs from the tip of the maximum cross-sectional area of the body. The point also comes in a number of different shapes (conventional cutting, reverse cutting, side cutting, taper cut, taper, blunt) (Figure 3-4).
4. The *chord* length is the straight line distance between the point of a curved needle and the swage.
5. The *radius* is the distance measured from the center of the circle to the body of the needle if the curvature of the needle was continued to make a full circle.

Needle Holder Selection

Ethicon (1985) gives the following pointers for selecting a needle holder:

1. Use an approximate size for the given needle. The smaller the needle, the smaller the needle holder required.
2. The needle should be grasped one-quarter to half the distance from the swaged area to the point, as shown in Figure 3-5.
3. The tips of the jaws of the needle holder should meet before the remaining portions of the jaws.
4. The needle should be placed securely in the tips of the jaws and should not rock, twist, or turn.
5. Do not overclose the needle holder. It should close only to the first or second ratchet. This will avoid damaging or notching the needle.
6. Pass the needle holder so that it is always directed by the surgeon's thumb.
7. *Do not use digital pressure on the tissue; this may puncture a glove.*

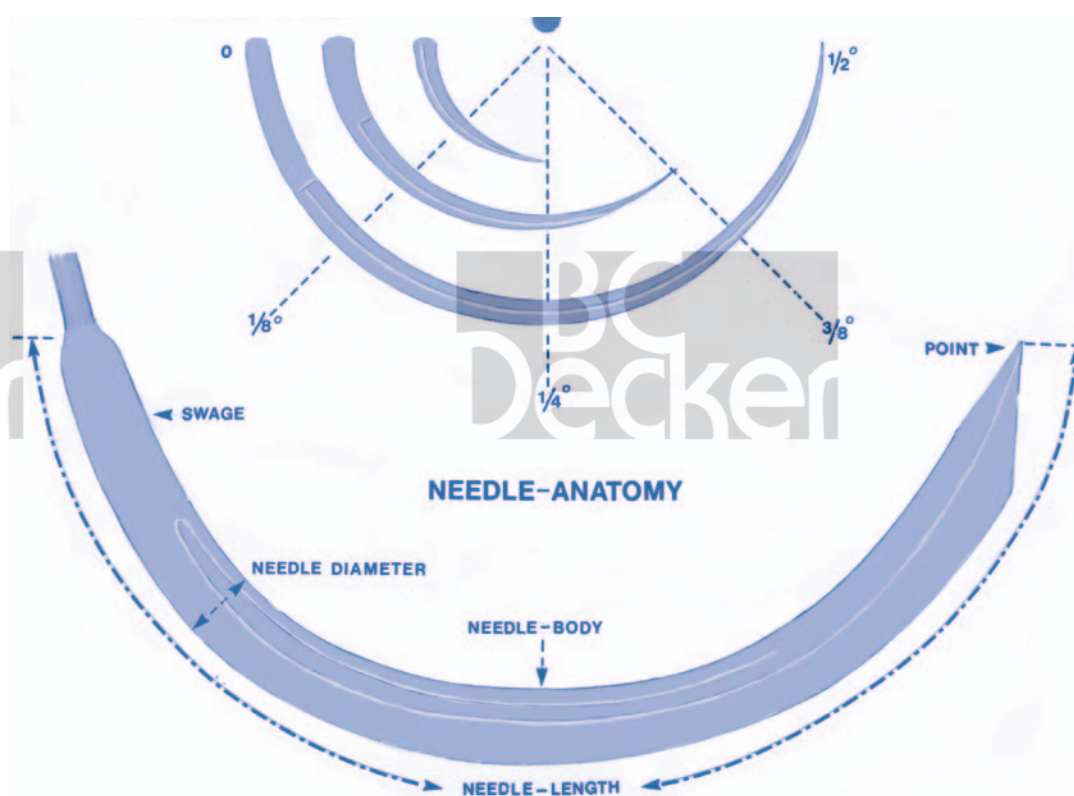


FIGURE 3-3. Needle anatomy. Needles are described by their arc. Most periodontal surgical needles are of three-eighths or one-half curvature. Different components of the needle are described.

Placement of Needle in Tissue

Ethicon (1985) gives the following principles for placing the needle in tissue:

1. Force should always be applied in the direction that follows the curvature of the needle.
2. Suturing should always be from movable to nonmovable tissue.
3. Avoid excessive tissue bites with small needles because it will be difficult to retrieve them.
4. Use only sharp needles with minimal force. Replace dull needles.
5. Grasp the needle in the body one-quarter to half the length from the swaged area. Do not hold the swaged area; this may bend or break the needle. Do not grasp the point area because damage or notching may result (see Figure 3-5).
 - a. Prior to suturing, the needle holder is repositioned to the forward half of the needle with a few millimeters of the tip, as shown in Figure 3-5.
6. The needle should always penetrate the tissue at right angles.
 - a. Never force the needle through the tissue.
7. Avoid retrieving the needle from the tissue by the tip. This will damage or dull the needle. Attempt to grasp the body as far back as possible.
9. An adequate tissue bite ($\geq 2-3$ mm) is required to prevent the flap from tearing.

Suturing Techniques

Different suturing techniques may employ either periosteal or nonperiosteal suture placement:

1. Interrupted
 - a. Figure eight
 - b. Circumferential director loop
 - c. Mattress—vertical or horizontal
 - d. Intrapapillary
2. Continuous
 - a. Papillary sling
 - b. Vertical mattress
 - c. Locking

The choice of technique is generally made on the basis of a combination of the individual operator's preference, educational background, and skill level, as well as surgical requirements.

Periosteal Suturing

Periosteal suturing generally requires a high degree of dexterity in both flap management and suture placement. Small needles (P-3), fine sutures (4-0 to 6-0), and proper needle holders are a basic requirement. Periosteal suturing permits precise flap placement and stabilization.

Technique

The five steps here are used in periosteal suturing (Chaiken, 1977) and are seen in Figure 3-6:

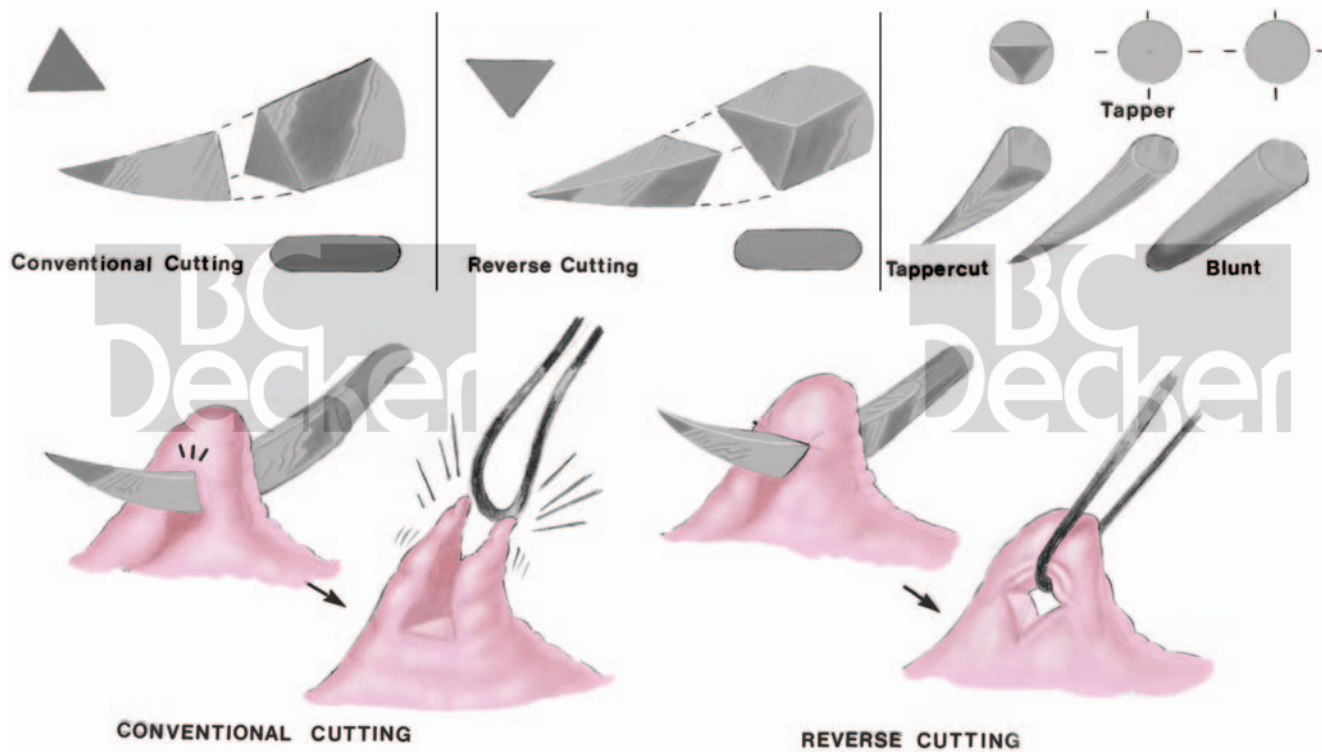


FIGURE 3-4. Cutting needles. Both outline and cross-sectional views of the various forms of cutting needle are shown. Conventional cutting and reverse cutting are also shown.

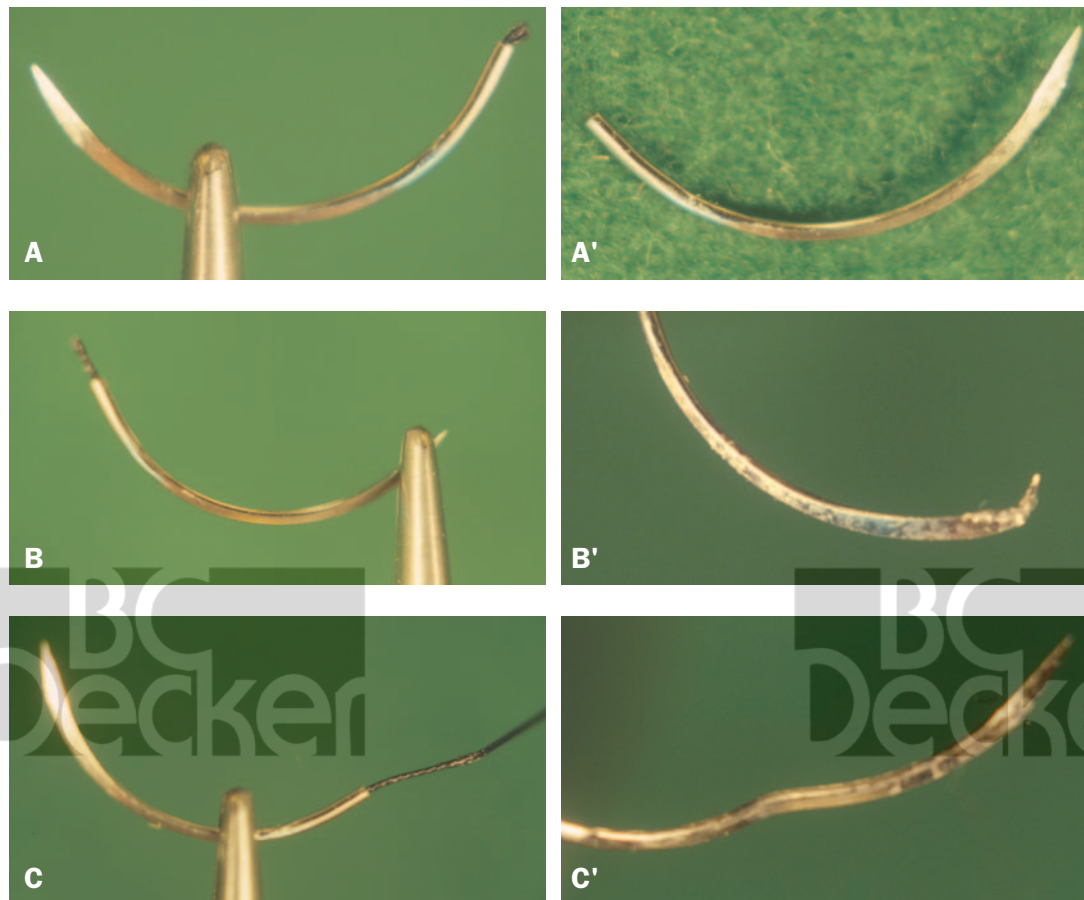


FIGURE 3-5. Correct handling of suture needles. *A*, Needle holder holding a suture needle just anterior to the curvature; *A'*, suture needle undamaged. *B*, Suture needle held incorrectly at tip; *B'*, tip of suture needle damaged. *C*, Suture needle held incorrectly behind curvature; *C'*, needle bent as a result.

1. *Penetration:* The needle point is positioned perpendicular (90°) to the tissue surface and underlying bone. It is then inserted completely through the tissue until the bone is engaged. This is as opposed to the usual 30° needle insertion angle (see Figure 3-6A).
2. *Rotation:* The body of the needle is now rotated about the needle point in the direction opposite to that in which the needle is intended to travel. The needle point is held tightly against the bone so as not to damage or dull the needle point (see Figure 3-6B).
3. *Glide:* The needle point is now permitted to glide against the bone for only a short distance. Care must be taken not to lift or damage the periosteum (see Figure 3-6C).
4. *Rotation:* As the needle glides against the bone, it is rotated about the body, following its circumferenced outline. In this way, the needle will not be pushed through the tissue, resulting in lifting or tearing of the periosteum (see Figure 3-6, D and E).
5. *Exit:* The final stage of gliding and rotation is needle exit. The needle is made to exit the tissue through the gentle application of pressure from above, thus allowing the tip to pierce the tissue. If digital pressure is to be used, care must be used to avoid personal injury (see Figure 3-6F).

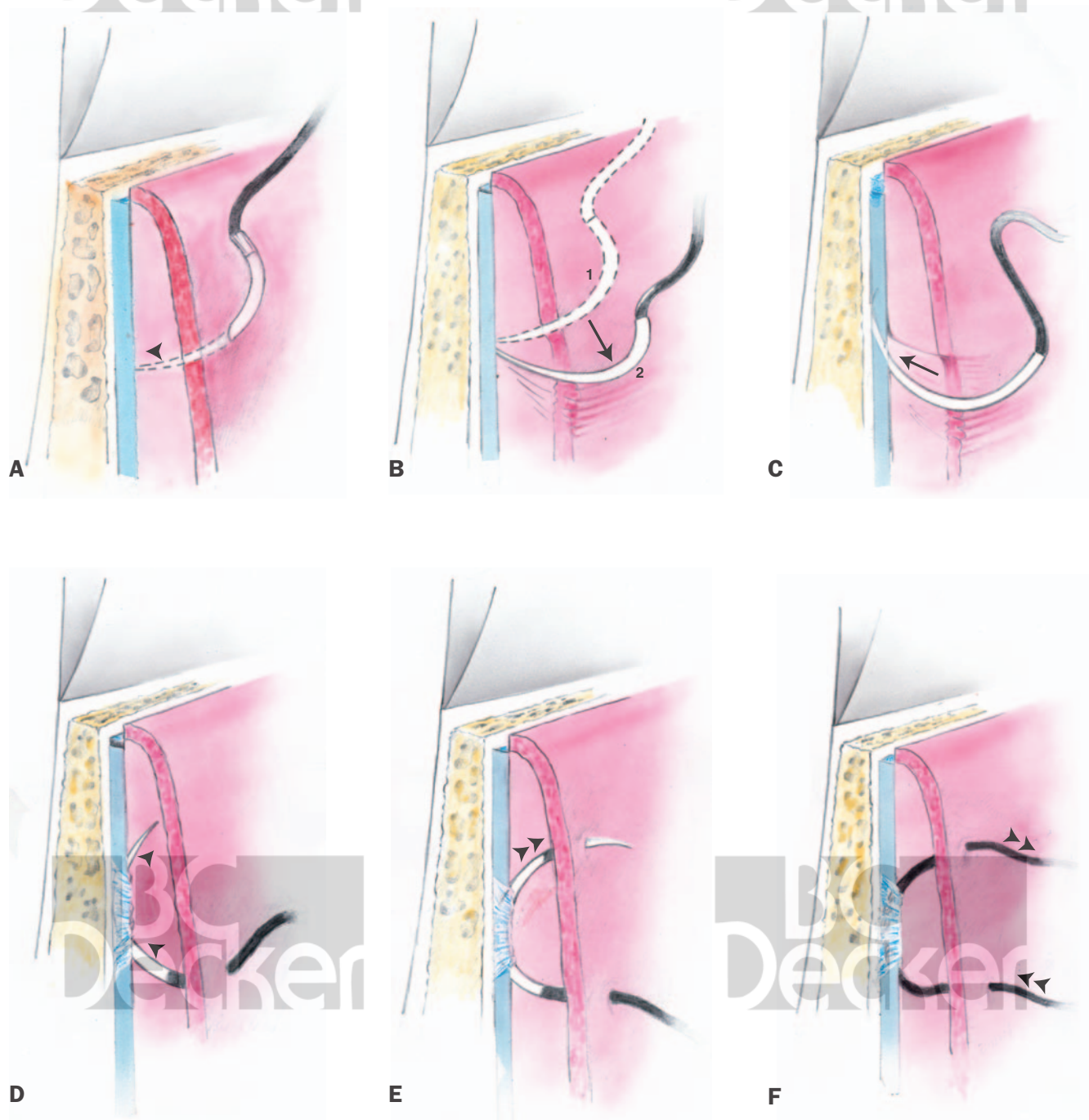


FIGURE 3-6. Periosteal suturing. *A*, Needle penetration; needle point is perpendicular to bone. *B*, Rotation of needle body about point. *C, D*, The needle is moved along the bone below the periosteum. *E*, Rotation about needle body permitting point to exit periosteum and tissue. *F*, Completed periosteal suture.

Interrupted Sutures

Indications

Interrupted sutures are most often used for the following:

1. Vertical incision
2. Tuberosity and retromolar areas
3. Bone regeneration procedures with or without guided tissue regeneration
4. Widman flaps, open flap curettage, unrepositioned flaps, or apically positioned flaps where maximum interproximal coverage is required
5. Edentulous areas
6. Partial- or split-thickness flaps
7. Osseointegrated implants

Types

In Figure 3-7, we see the four most commonly used interrupted sutures:

1. Circumferential, direct, or loop (see Figure 3-7A)
2. Figure eight (see Figure 3-7B)
3. Vertical or horizontal mattress (see Figure 3-7C)
4. Intrapapillary placement (see Figure 3-7D)

Technique

Figure Eight and Circumferential Sutures. Suturing is begun on the buccal surface 3 to 4 mm from the tip of the papilla to prevent tearing of the thinned papilla. The needle is first inserted into the outer surface of the buccal flap and then either through the outer epithelialized surface (figure eight) (Figure 3-8) or the connective tissue under the surface (circumferential) (see Figure 3-8A) of the lingual flap. The needle is then returned through the embrasure and tied buccally.

When interproximal closure is critical, the circumferential suture will permit greater coaptation and tucking down of the papilla because of the lack of intervening suture material between the tips of the papilla.

Mattress Sutures. Mattress sutures are used for greater flap security and control; they permit more precise flap placement, especially when combined with periosteal stabilization. They also allow for good papillary stabilization and placement. *The vertical mattress (nonperiosteal) suture is recommended for use with bone regeneration procedures because it permits maximum tissue clo-*

sure while avoiding suture contact with the implant material, thus preventing wicking. They are left for 14 to 21 days (Mejias, 1983) and therefore require a suitable material (eg, nylon, e-PTFE) that is biologically inert and does not rapidly “wick.”

Vertical Mattress Technique. The flap is stabilized and a P-3 needle is inserted 7 to 10 mm apical to the tip of the papilla. It is passed through the periosteum (if periosteal sutures are being used), emerging again from the epithelialized surface of the flap 2 to 3 mm from the tip of the papilla. The needle is brought through the embrasure, where the technique is again repeated lingually or palatally. The suture is then tied buccally (Figure 3-9A).

Horizontal Mattress Technique. A P-3 needle is inserted 7 to 8 mm apical to and to one side of the midline of the papilla, emerging again 4 to 5 mm through the epithelialized surface on the opposing side of the midline (Figure 3-9B). The suture may or may not be brought through the periosteum. The needle is then passed through the embrasure, and the suture, after being repeated lingually or palatally, is tied buccally. For greater papillary stability and control, the double parallel

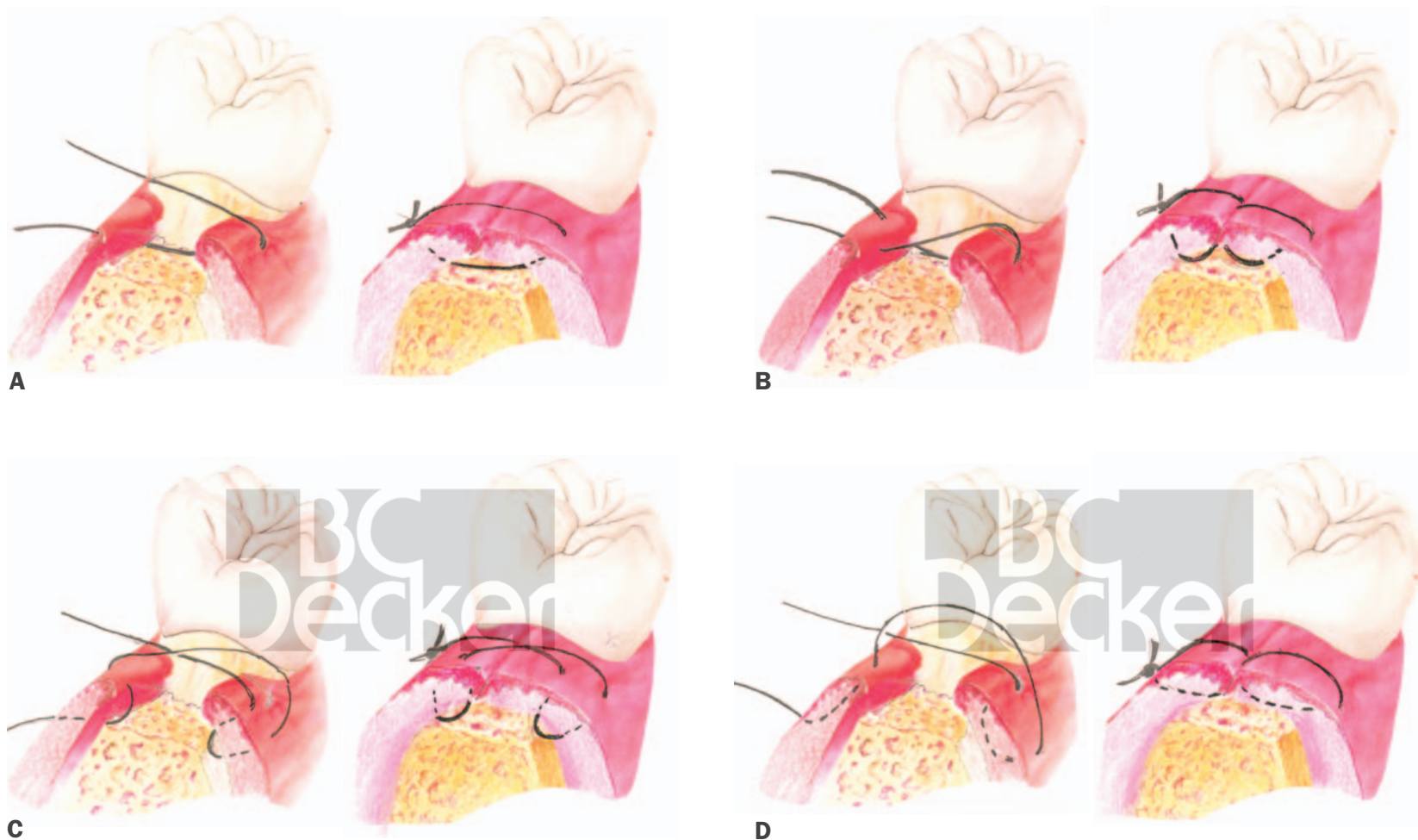


FIGURE 3-7. Four interrupted sutures. A, Circumferential. B, Figure-eight. C, Vertical mattress. D, Intrapapillary.

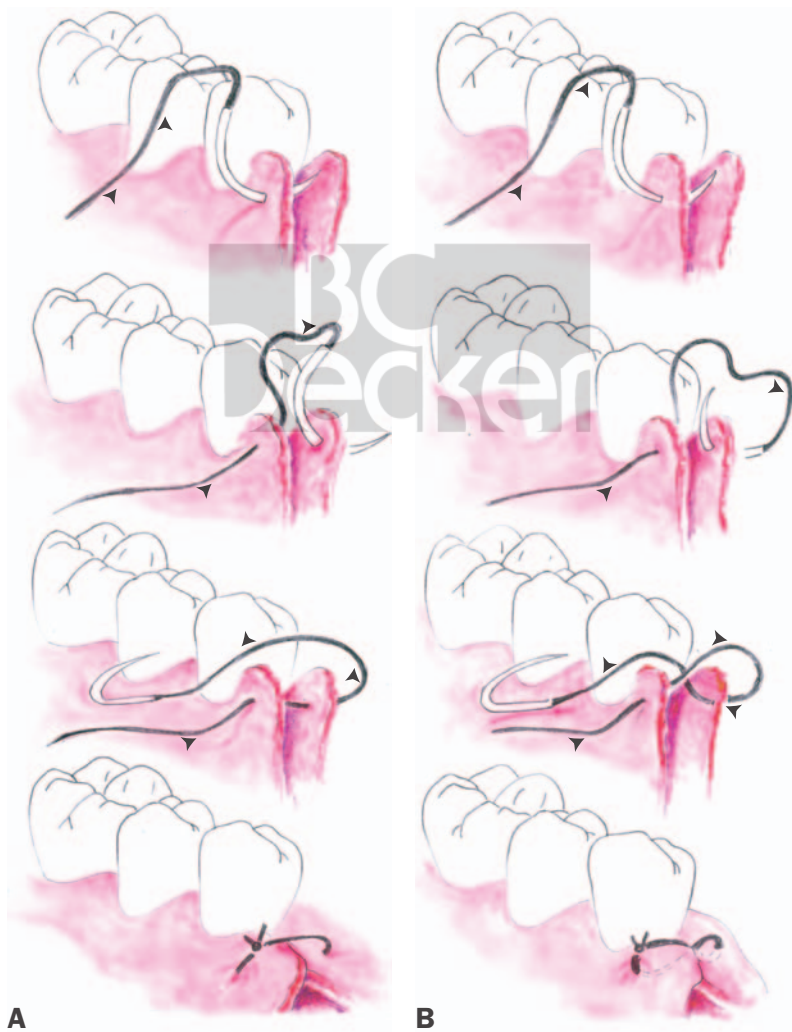

FIGURE 3-8. A, Circumferential suture. B, Figure-eight suture.

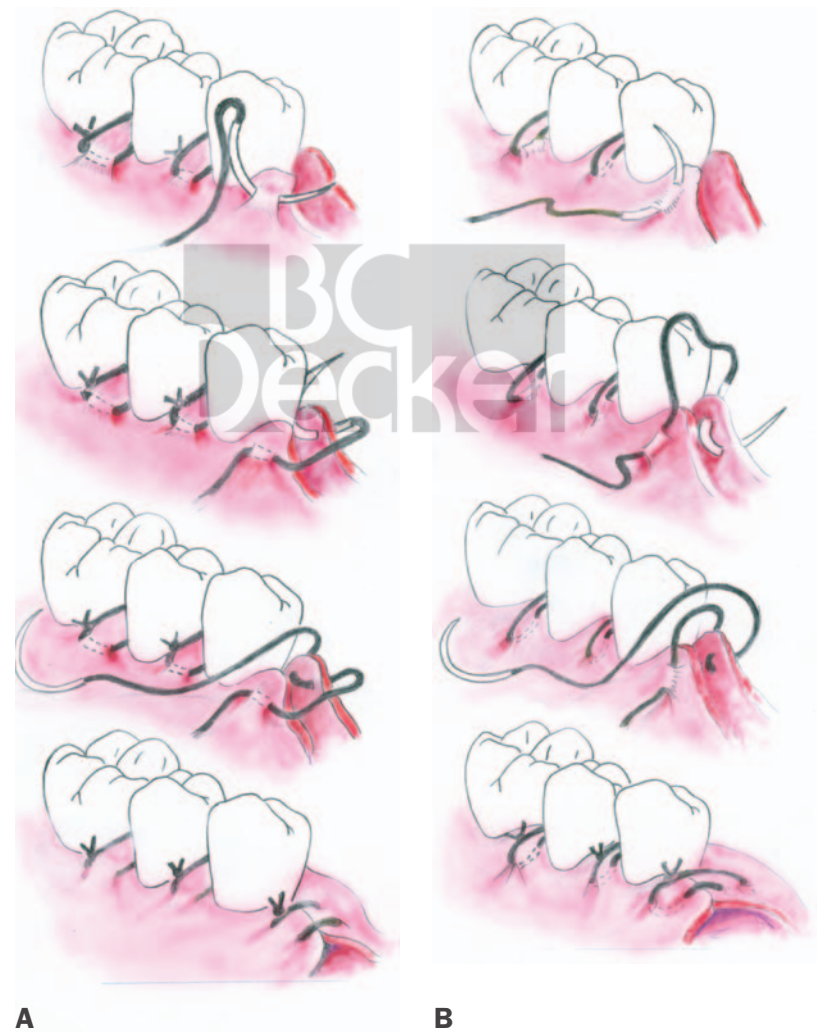


FIGURE 3-9. A, Horizontal mattress suture. B, Vertical mattress suture.

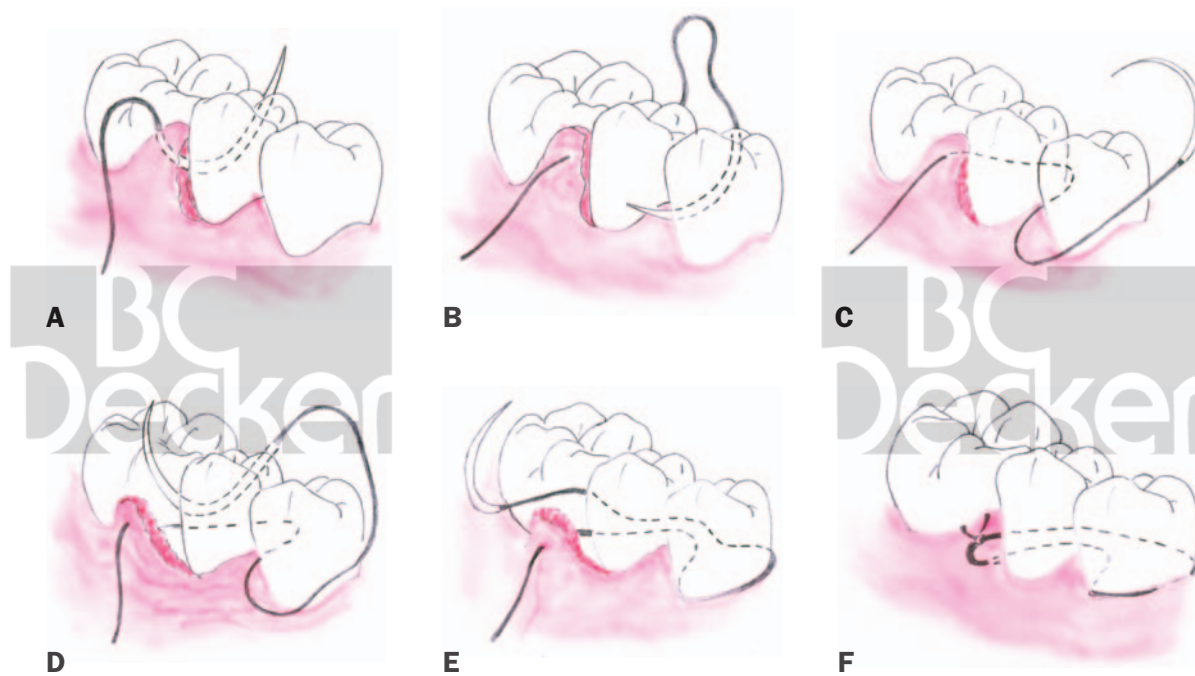


FIGURE 3-10. Sling suture about adjacent tooth.

strands of this suture can be made to cross over the three tops of the papillae. This is the double crossed-over suture.

Intrapapillary Placement. *This technique is recommended for use only with modified Widman flaps and regeneration procedures in which there is adequate thickness of the papillary tissue.*

A P-3 needle is inserted buccally 4 to 5 mm from the tip of the papilla and passed through the tissue, emerging from the very tip of the papilla. This is repeated lingually and tied buccally, thus permitting exact tip-to-tip placement of the flaps (see Figure 3-7D).

Sling Suture. The sling suture is primarily used for a flap that has been raised on only one side of a tooth, involving only one or two adjacent papillae. It is most often used in coronally and laterally positioned flaps. The technique involves use of one of the interrupted sutures, which is either anchored about the adjacent tooth (Figure 3-10) or slung around the tooth to hold both papillae (Figure 3-11).

Specialized Interrupted Suturing Techniques for Bone Regeneration and Retromolar and Tuberosity Areas. *Laurell Modification.* Laurell modified mattress suture (1993) (Figure 3-12) for coronal flap positioning and primary flap coverage is a technique which, although capable of being employed for all regenerative techniques, is used

predominantly when standard interproximal incisions are used. Start buccally below the papilla (2–4 mm) and insert the needle to and then through the undersurface of the lingual flap (Figure 3-12A1). The suture needle is then reinserted lingually 2–4 mm above the initial suture and continued to and then through the buccal flap (Figure 3-12A2). The suture is then brought lingually over the coronal aspect of the flap and through the loop (Figure 3-12A3). The suture is afterwards returned buccally and sutured (Figure 3-12A4). Figure 3-12B shows the completed suture.

Modified Flap Suturing Technique. This technique (Cortellini et al 1995) was introduced specifically for achieving maximum interproximal coverage and primary closure over intrabony defect is treated by GTR. The modified flap technique (Figure 3-13) requires the initial incision be made at the buccal line angles in the area of the interproximal defect. It is a papillary preservation technique. The suturing permits coronal positioning, flap stabilization, and primary interproximal closure. The first suture is begun buccally 5–6 mm below the initial incision (Figure 3-13A1). The suture is passed through the buccal and palatal flaps. It is then reinserted palatally and allowed to exit the buccal flap 2 mm above the initial placements. This is tied off and should stabilize the body of the flap. The second suture is now begun 3–4 mm below the initial inci-

sion and above the first suture (Figure 3-13A2). The suture is passed through the interproximal papilla and returned as a horizontal mattress suture on the buccal surface and tied off.

Retromolar Suture Modification for Primary Coverage. This technique (Hutchenson 2005) (Figure 3-14) is specially designed for gaining intimate tissue-tooth contact where regeneration is being attempted. It is employed when there is an intrabony defect distal to the last tooth on the lower teeth. It not only permits primary flap closure but close approximation of the tissue on the distal aspect of the tooth. Figure 3-14A shows a defect distal to the last tooth. The arrows on Figure 3-14B indicates desired movement of flap and dotted lines indicate ideal flap position. Flap ideally should be positioned against distal surface of tooth with primary closure. Suture is begun on the mesiobuccal of the terminal tooth (Figure 3-14C1). The suture is passed through interproximal to the distal and inserted through only the undersurface of the buccal flap. The suture is brought almost 360° around the tooth starting lingually and continuing buccally until again reaching the distal surface (Figure 3-14C2). The needle is passed through the undersurface of the lingual flap and tied on the buccal surface (Figure 3-14C3). Figure 3-14D shows suturing having been completed and primary coverage attained.

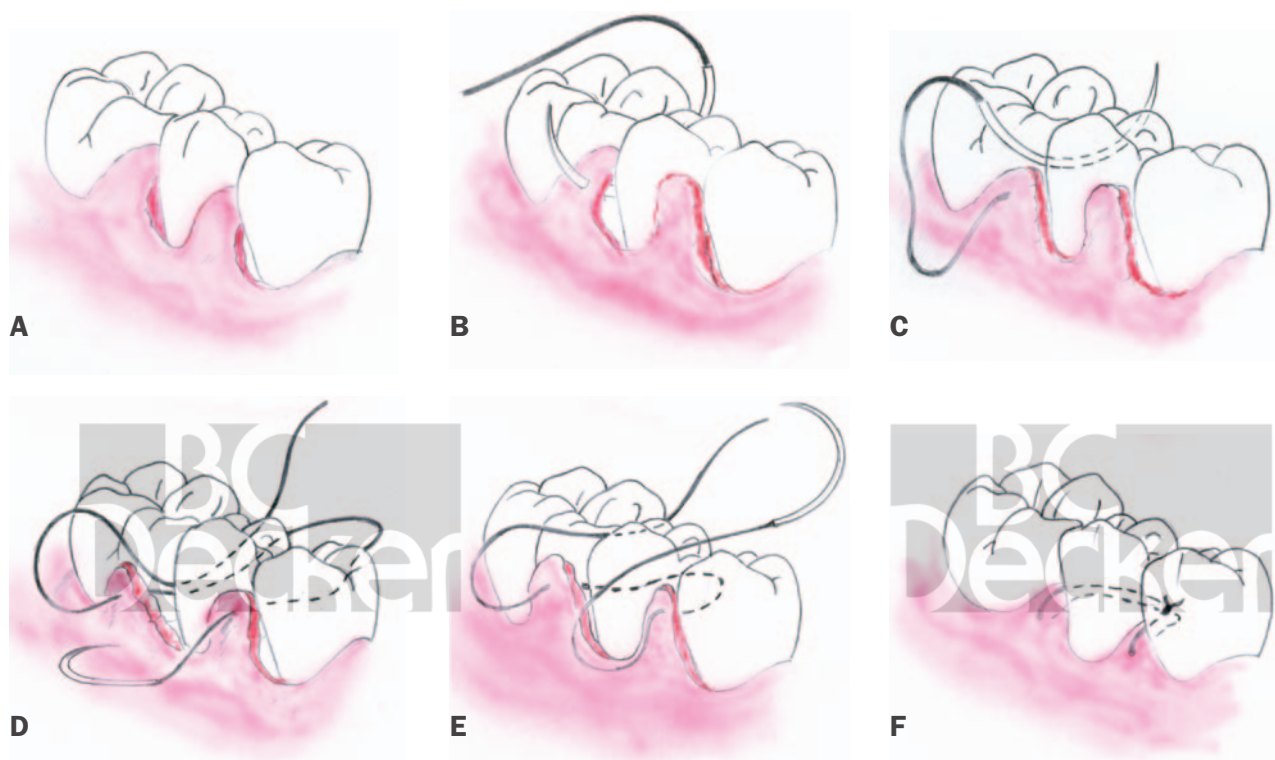


FIGURE 3-11. Sling suture about single tooth.

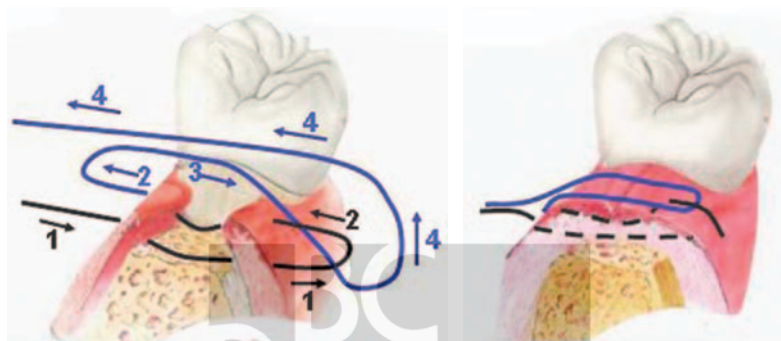


FIGURE 3-12. Laurell modified mattress suture (see text).

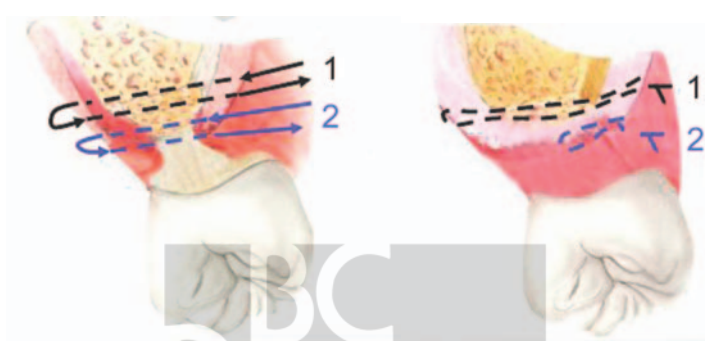


FIGURE 3-13. Modified flap suturing technique (see text).

Continuous Sutures Sling

When multiple teeth are involved, the continuous suture is preferred.

Advantages

1. Can include as many teeth as required
2. Minimizes the need for multiple knots
3. Simplicity
4. The teeth are used to anchor the flap
5. Permits precise flap placement
6. Avoids the need for periosteal sutures
7. Allows independent placement and tension of buccal and lingual or palatal flaps. Buccal flaps can be positioned loosely, whereas lingual and palatal flaps are pulled more tightly about the teeth.
8. Greater distribution of forces on the flaps

Disadvantages

The main disadvantage of continuous sutures is that if the suture breaks, the flap may become

loose or the suture may come untied from multiple teeth.

Types

The choice of continuous suture depends on the operator's preference. These, too, can be periosteal or nonperiosteal:

1. Independent sling suture
2. Mattress sutures
 - a. Vertical
 - b. Horizontal
3. Continuous locking

Technique

Independent Sling Suture

The continuous sling suture (Figure 3-15), although most often begun as a continuation of tuberosity or retromolar suturing (see Figure 3-15A), can also be started with a looped suture about the terminal papilla (buccal, lingual, or palatal). It is then continued through the next

interproximal embrasure (see Figure 3-15B) in such a manner that the suture is made to encircle the neck of the tooth (see Figure 3-15C). The needle is then passed either over the papilla and through the outer epithelialized surface or underneath and through the connective tissue under-surface of the papilla. The needle is passed again through the embrasure and continued anteriorly (Figure 3-15D). This procedure is repeated through each successive embrasure until all papillae have been engaged.

Note: For maximum flap control, it is best to pass the needle through the connective tissue under-surface of the papilla.

A terminal end loop (Figure 3-15E) is then used if a single flap has been reflected or if the flaps are to be sutured independently. In this manner, the flaps are tied against the teeth as opposed to each other.

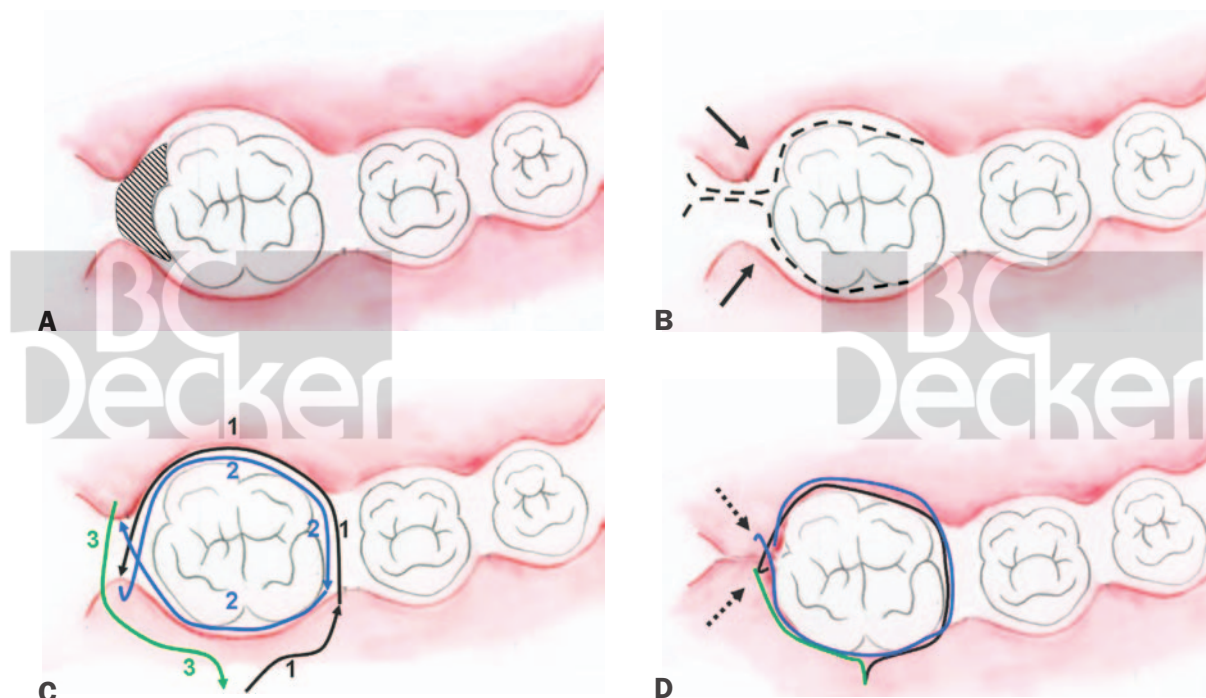


FIGURE 3-14. Retromolar area modified suture technique (see text).

Terminal End Loop. On completion of suturing, the suture is tied off against the tooth as opposed to the other flap. This is accomplished by leaving a loose loop of approximately 1 cm length of suture material before the last embrasure. When the last papilla is sutured and the needle is returned through the embrasure, the terminal end loop is used to tie the final knot (Figure 3-15F-I).

Modification. When two flaps have been reflected and after the first flap has been sutured (Figure 3-16A), it is often desirable to continue about the distal surface of the last tooth (Figure 3-16B), repeating the procedure on the opposing flap (Figure 3-16C) and then tying off in a terminal end loop (Figure 3-16D and E).

Alternative Procedure. This technique simultaneously slings together both the buccal and lingual or palatal flaps.

INDICATIONS.

1. When flap position is not critical
2. When buccal periosteal sutures are used for buccal flap position and stabilization
3. When maximum closure is desired (unreposition or Widman flaps or bone regeneration)

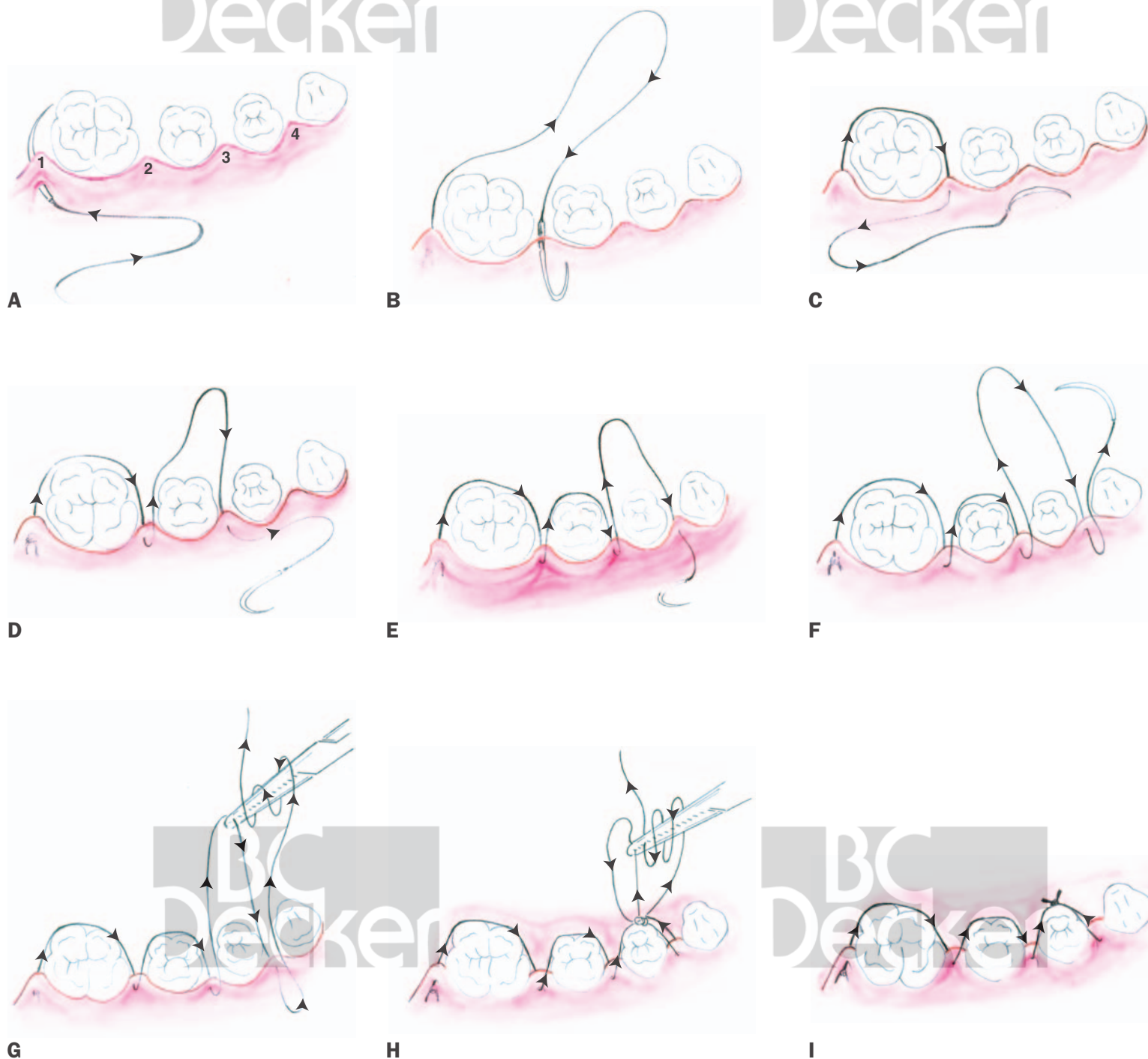


FIGURE 3-15. Continuous sling suture with terminal end loop.

Technique

After the initial buccal and lingual tie, the suture is passed buccally about the neck of the tooth interdentially and through the lingual flap. It is then again brought interdentially through the buccal papilla and back interdentially about the lingual surface of the tooth to the buccal papilla. Then it is brought about the lingual papilla and then the buccal surface of the tooth. This alternating buccal-lingual suturing is continued until the suture is tied off with a terminal end loop (Figure 3-17).

Vertical and Horizontal Mattress Suture. When greater papillary control and stability and more precise placement are required or to prevent flap movement, vertical or horizontal mattress sutures are used. This is most often the case on the palate, where additional tension is often required, or when the papillary tissue is thin and friable.

Technique. The procedure is identical to that previously described for the independent papillary sling suture (see Figure 3-15), except that vertical or horizontal mattress sutures are substituted for the simple papillary sling. The technique is similar to that previously described for the interrupted mattress sutures.

Locking. The continuous locking suture is indicated primarily for long edentulous areas, tuberosities, or retromolar areas. It has the advantage of avoiding the multiple knots of interrupted sutures. If the suture is broken, however, it may completely untie.

Technique. The procedure is simple and repetitive. A single interrupted suture is used to make the initial tie. The needle is next inserted through the outer surface of the buccal flap and the underlying surface of the lingual flap. The needle is then passed

through the remaining loop of the suture, and the suture is pulled tightly, thus locking it. This procedure is continued until the final suture is tied off at the terminal end (Figure 3-18).

Suture Removal

Sutures are used for wound stabilization and should be removed when sufficient tissue strength has been achieved. This is usually between 5 and 10 days, and in most instances, these sutures are removed in 7 days.

Materials

1. Scissors
2. Cotton pliers
3. Double-ended scaler
4. Hydrogen peroxide
5. Topical anesthetic
6. Cotton swabs

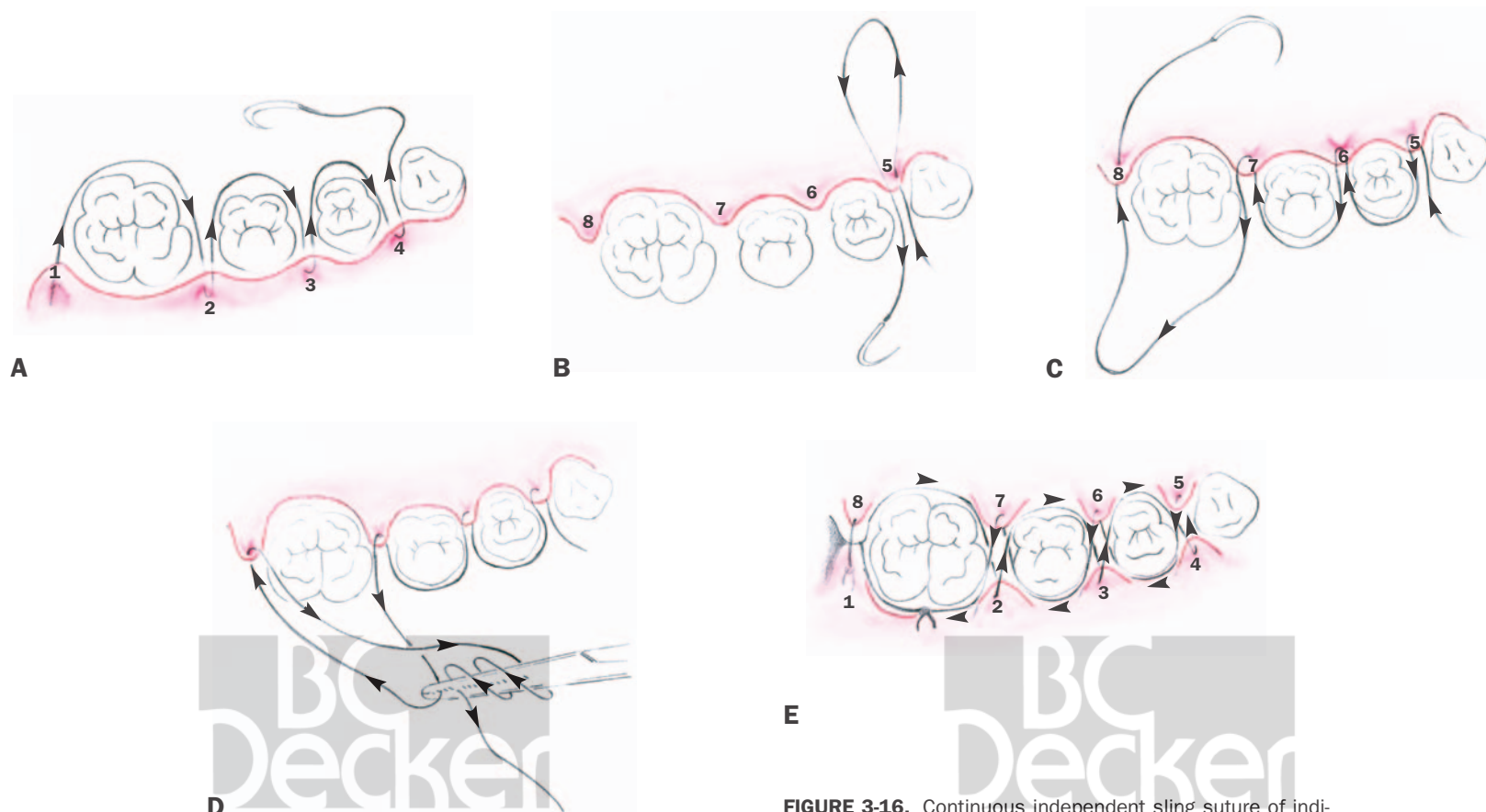
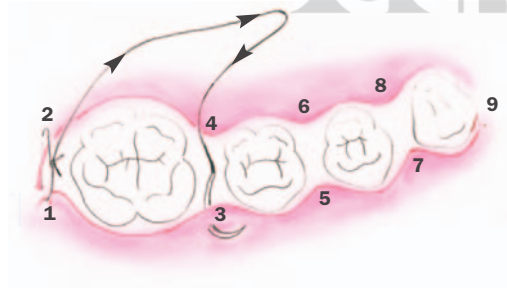


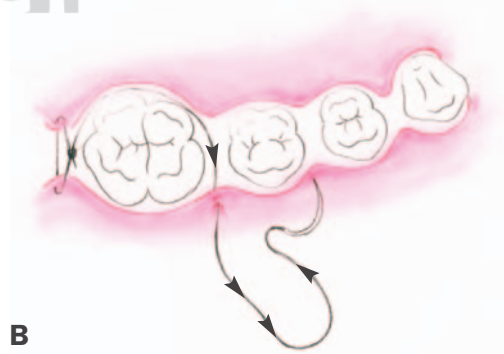
FIGURE 3-16. Continuous independent sling suture of individual flaps.

Method

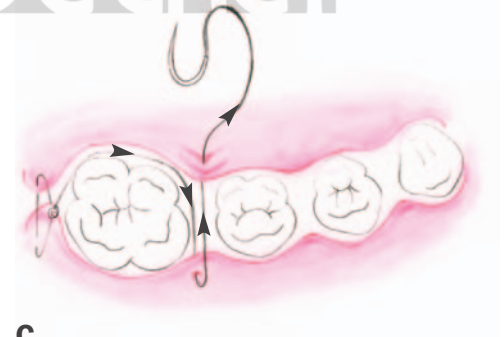1. The scaler is used to remove the dressing. The dressing should be loosened first in an apicoronal direction. This will place the tension against the teeth and not the tissue.
2. The area is then gently swabbed with hydrogen peroxide to move clotted blood, serum, and debris and is rinsed with warm water.
3. Topical anesthetic may be optionally applied
4. A sharp scissors should be used to cut the loops of the individual or continuous sutures. **Note: It is often helpful to use the tip of an explorer to gently lift the suture off the tissue prior to cutting.** This will avoid tissue damage and unnecessary pain.
5. Interrupted sutures need be cut only on the facial aspect close to the tissue.
6. Continuous sutures will require cutting both buccally and lingually.
7. Once the sutures are removed, the area should again be swabbed with hydrogen peroxide or chlorhexidine gluconate to remove any residual debris.
8. The teeth should be polished for complete removal of debris and stain.
9. Plaque control should again be reviewed.



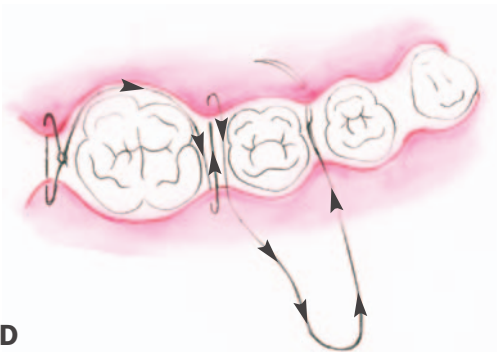
A



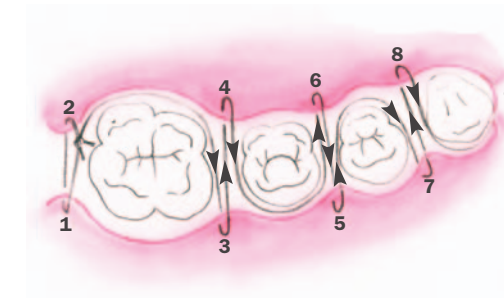
B



C



D



E

FIGURE 3-17. Modification of continuous sling suture. This technique permits simultaneous suturing of both flaps.

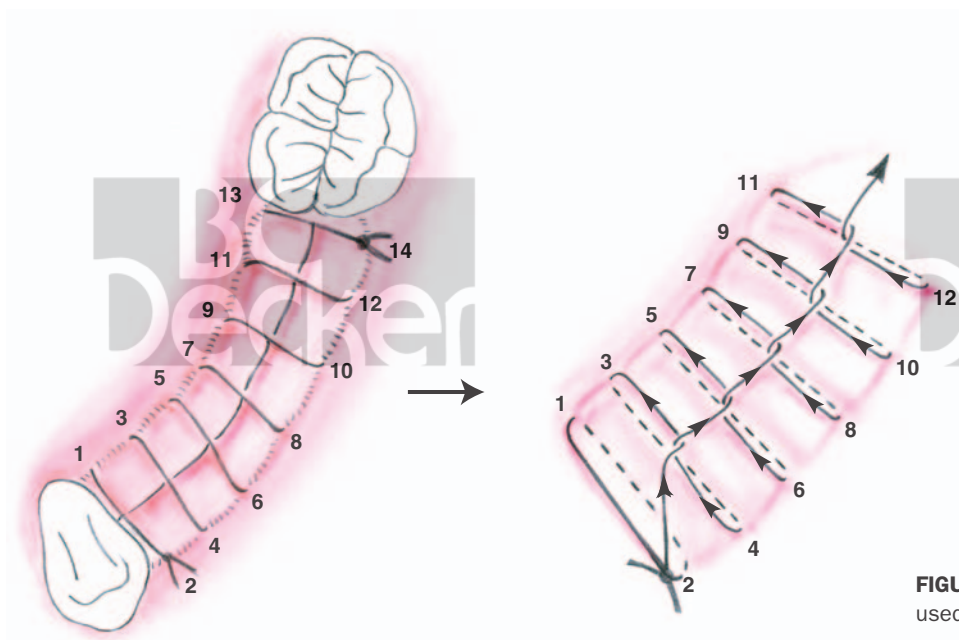


FIGURE 3-18. Continuous locking suture used primarily for edentulous areas.