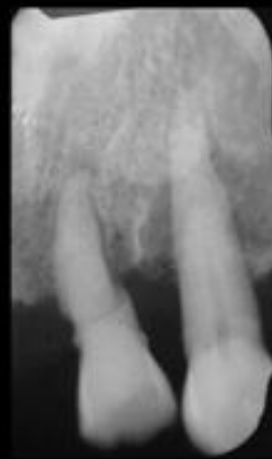
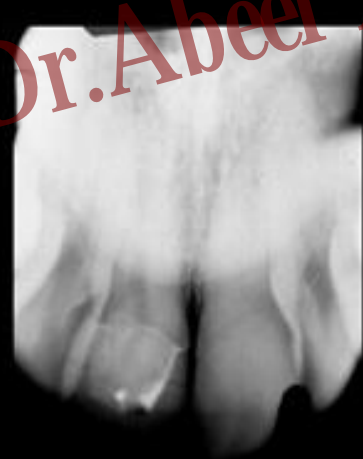
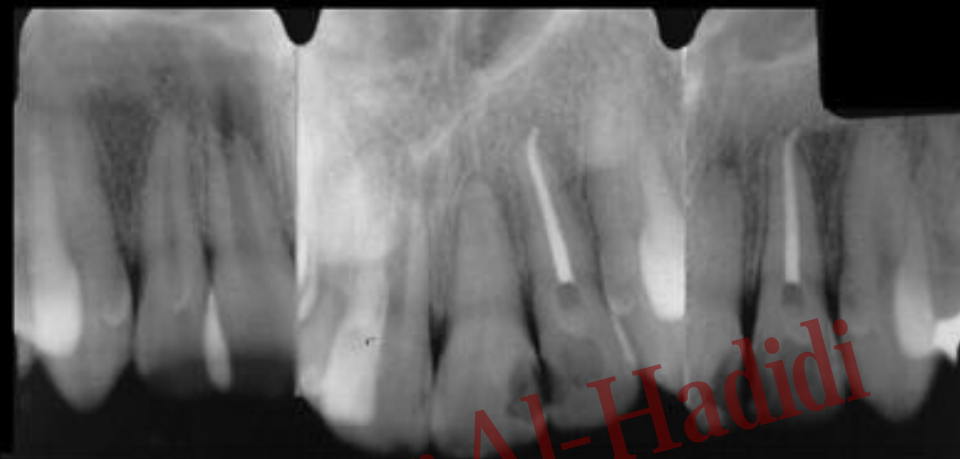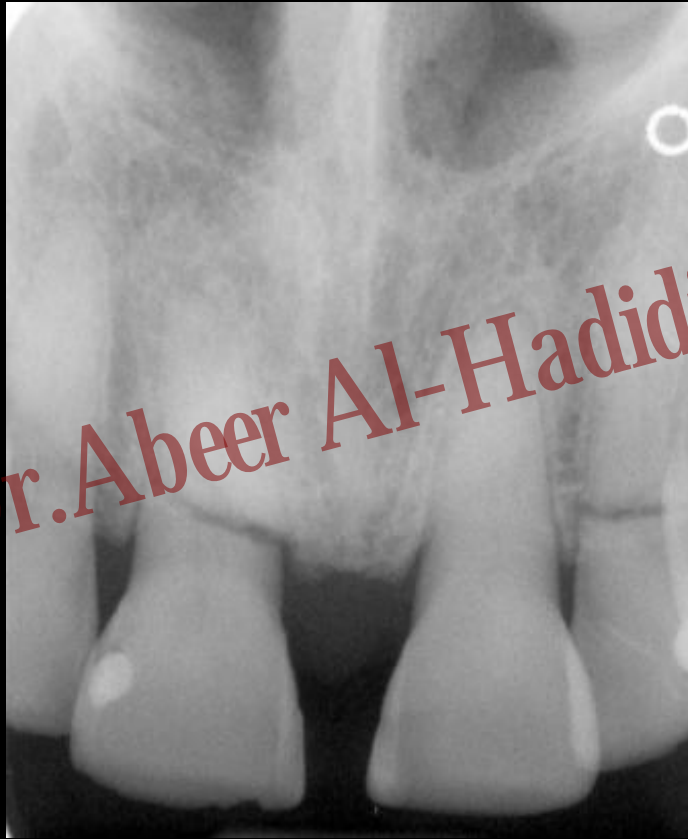CRC#3

Dr. Abeer Al-Hadidi

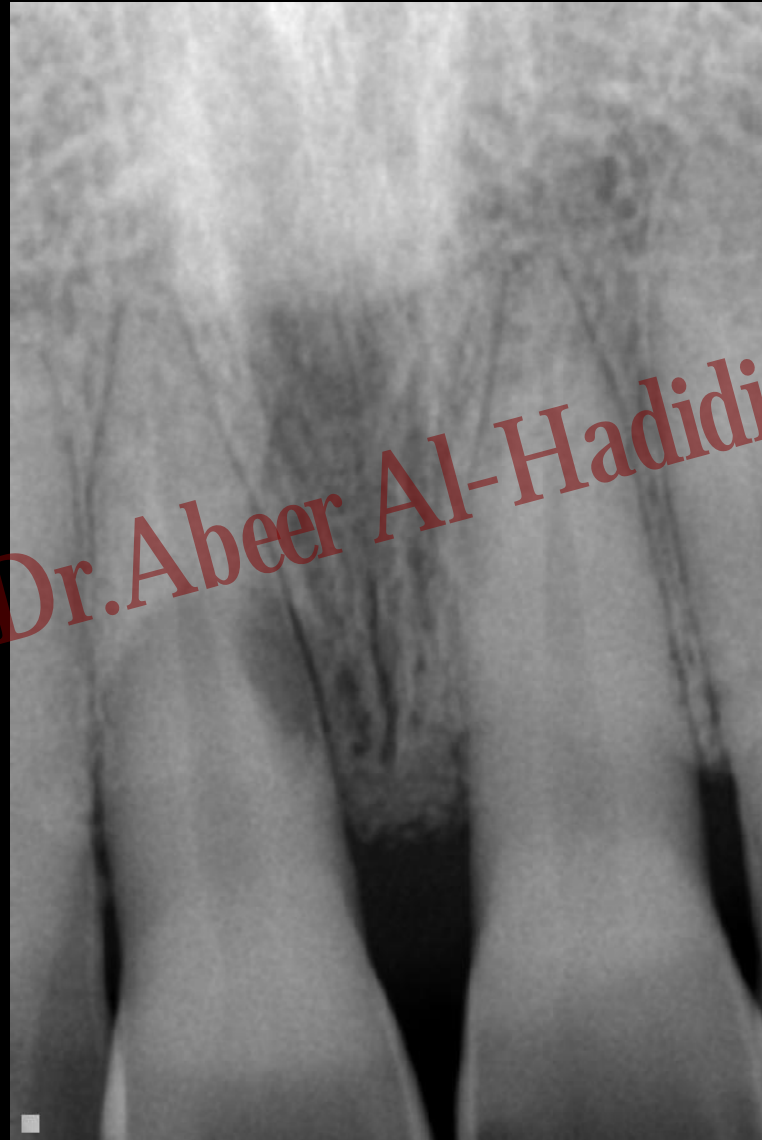Case 1:



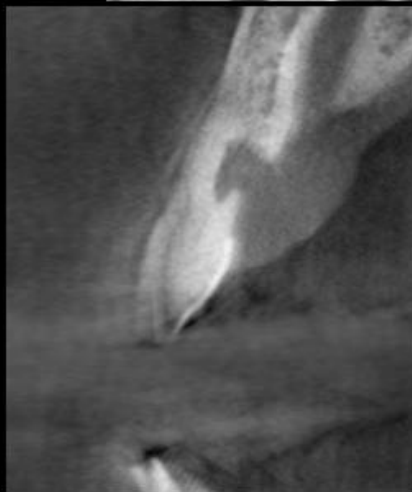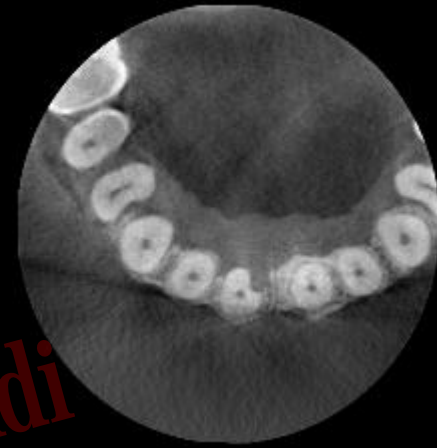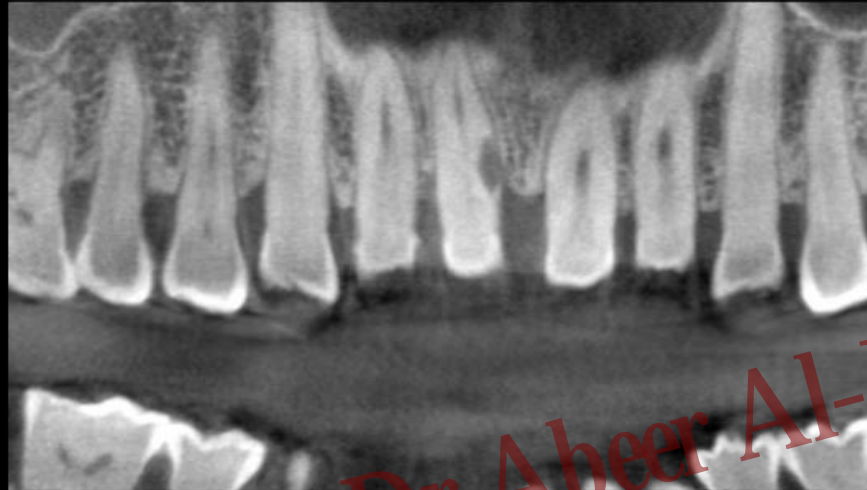
Dr. Abeer Al-Hadidi



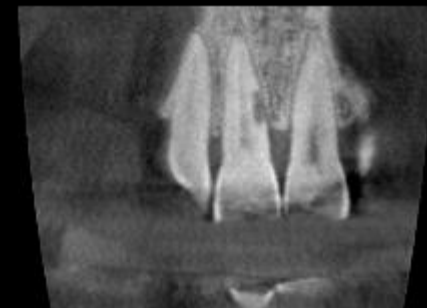
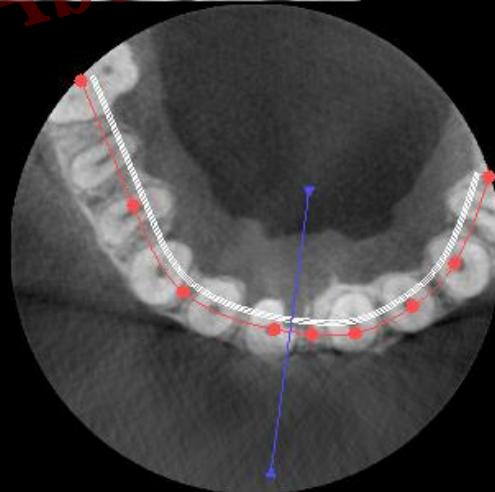
Case 2



Case 2



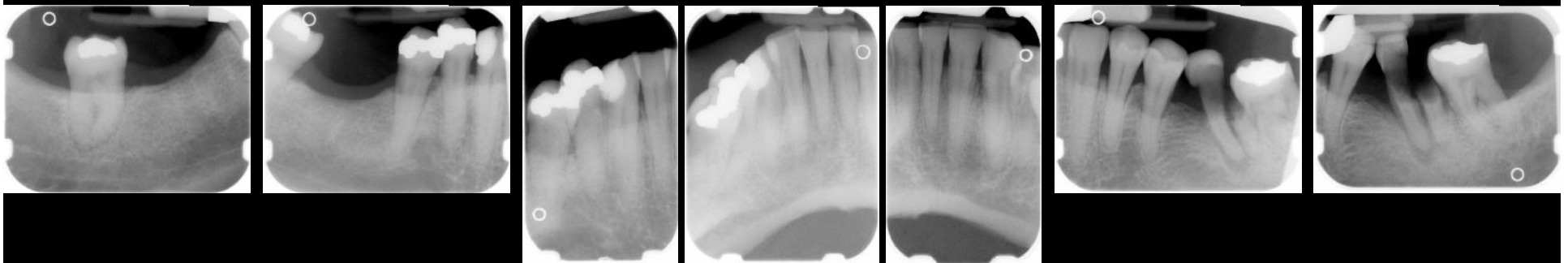
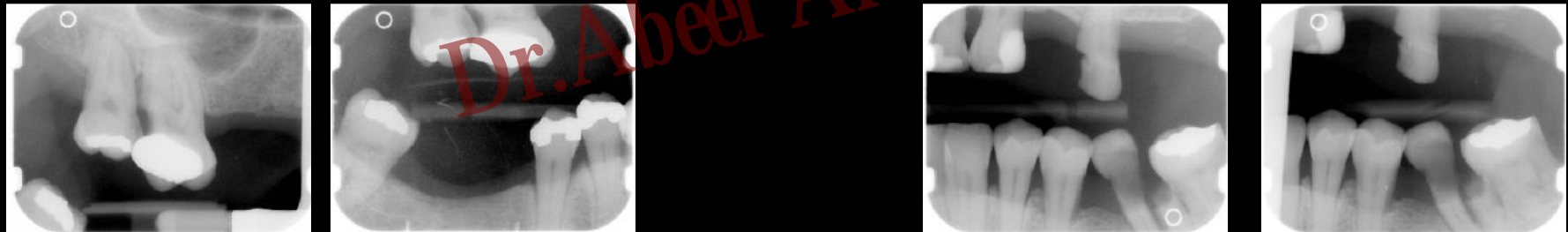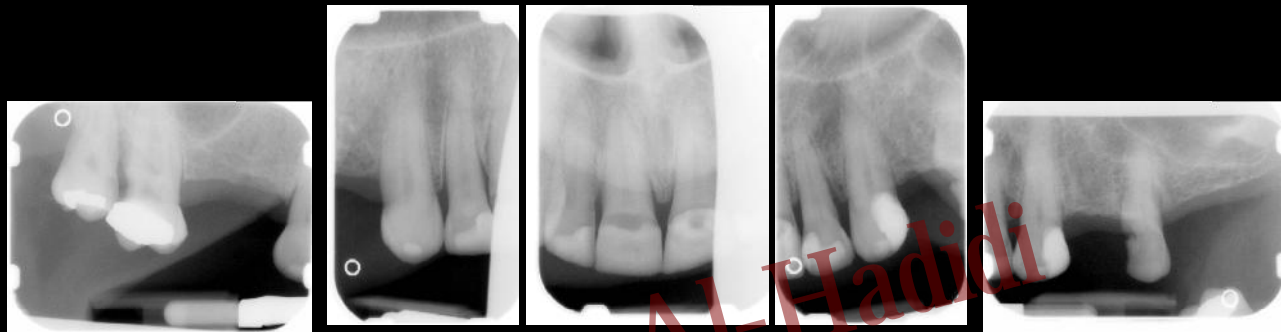
Dr. Abeer Al-Hadidi



Case 3

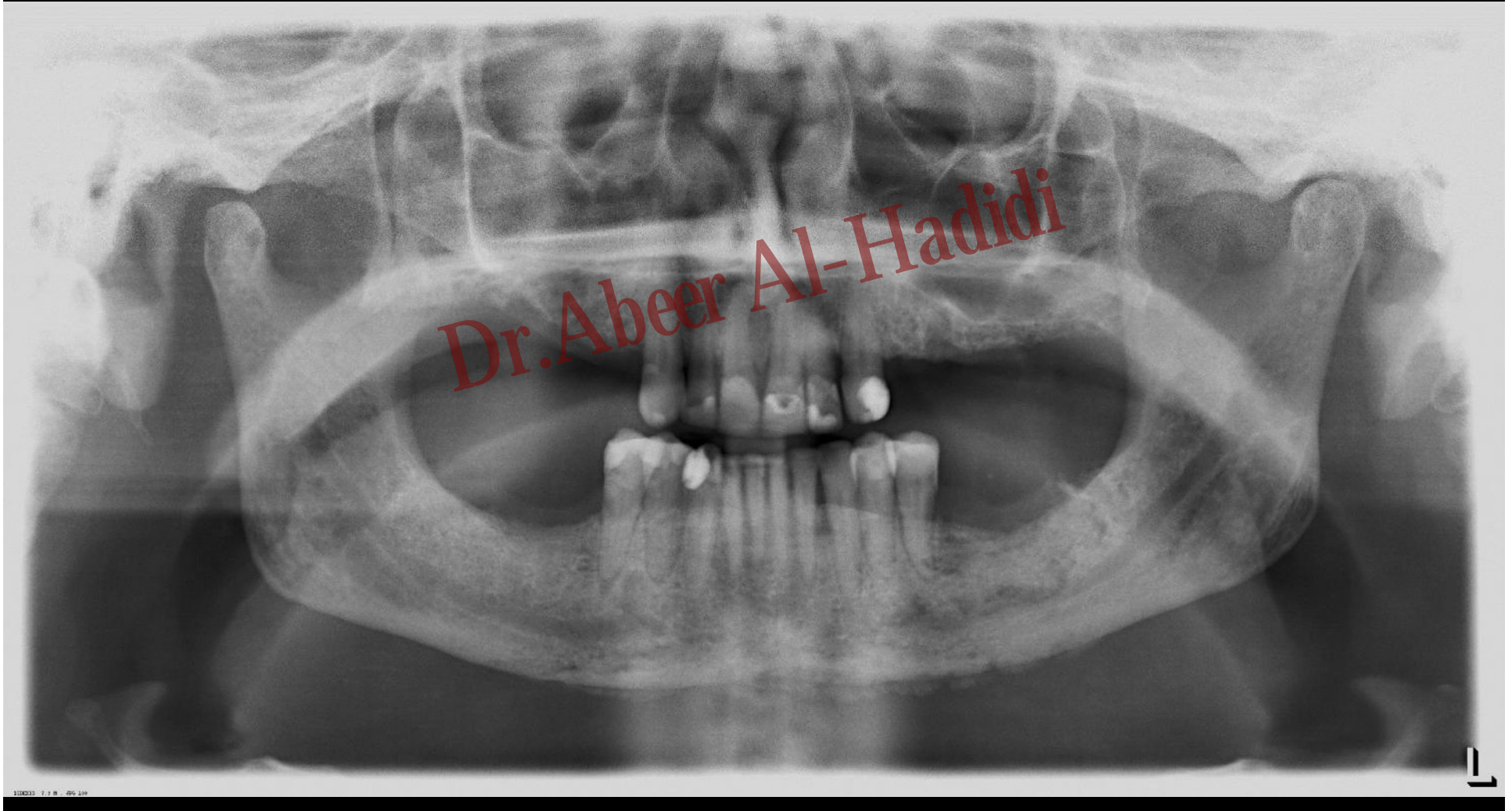- ▣ 60 year old female
- ▣ Medical History
 - Meds include:
 - ▣ Metformin, Xanax, Protonix, Oxycontin, Pangestyme, Fish Oil, Calcium, Milk Thistle
- ▣ Dental History
 - TMJ right and left click
 - Erythematic hyperplasia midline of soft palate
 - Attrition
 - Decreased vertical dimension
 - Moderate Periodontitis
 - Originally accepted to dental student clinics for partial dentures (see her FMX (taken 2008))
 - 3 and 19 extracted due to dental caries
 - patient discontinued treatment due to medical problems
 - Patient returned to Urgent Care. See pan from 2011

Full Mouth Series from 2008

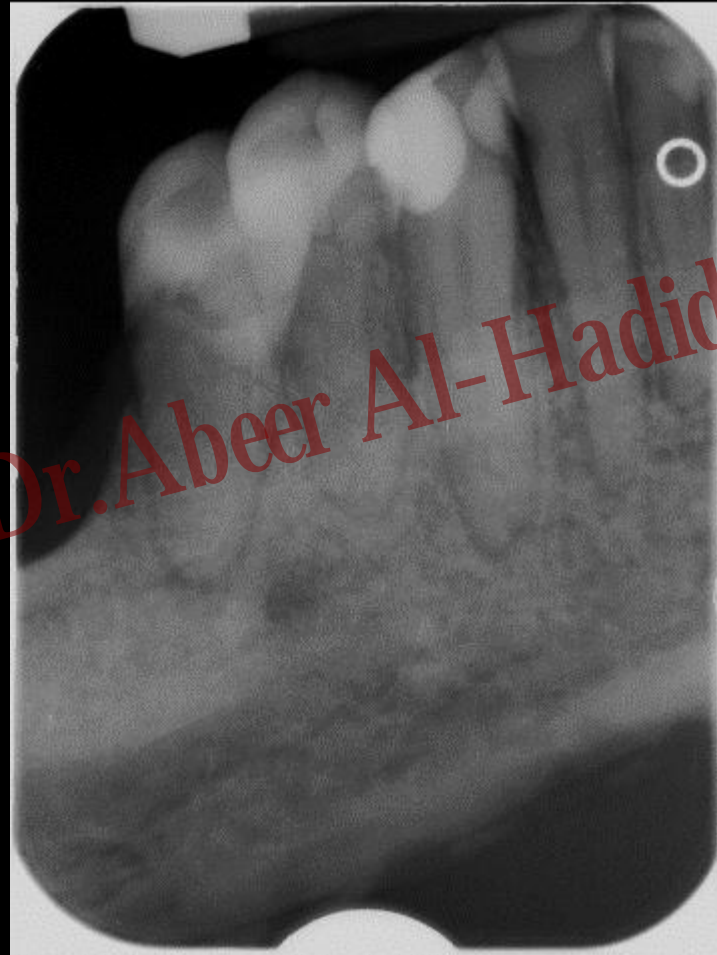


Dr. Abeer Al-Hadidi

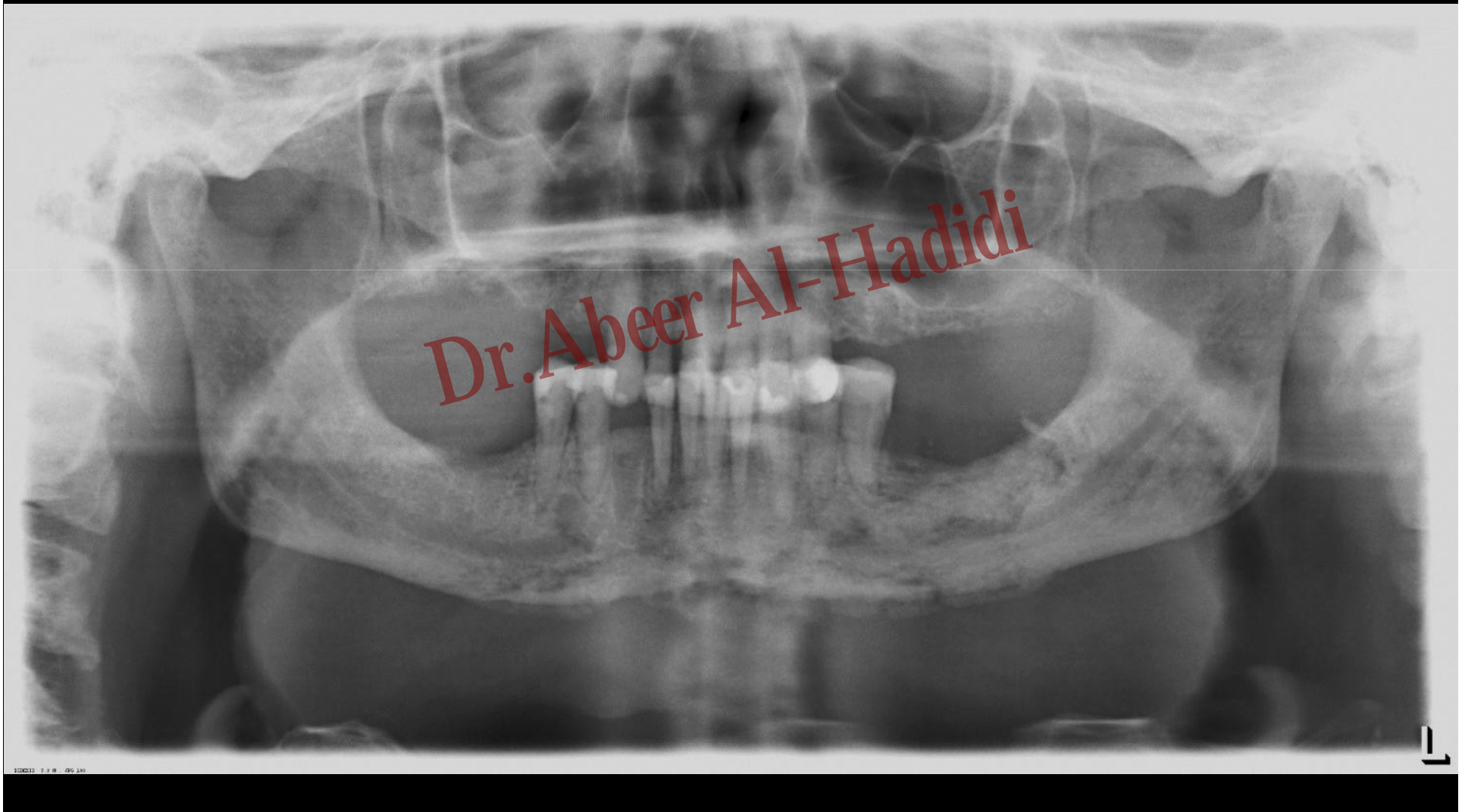Case Pan taken in Urgent Care 02-08- 2011



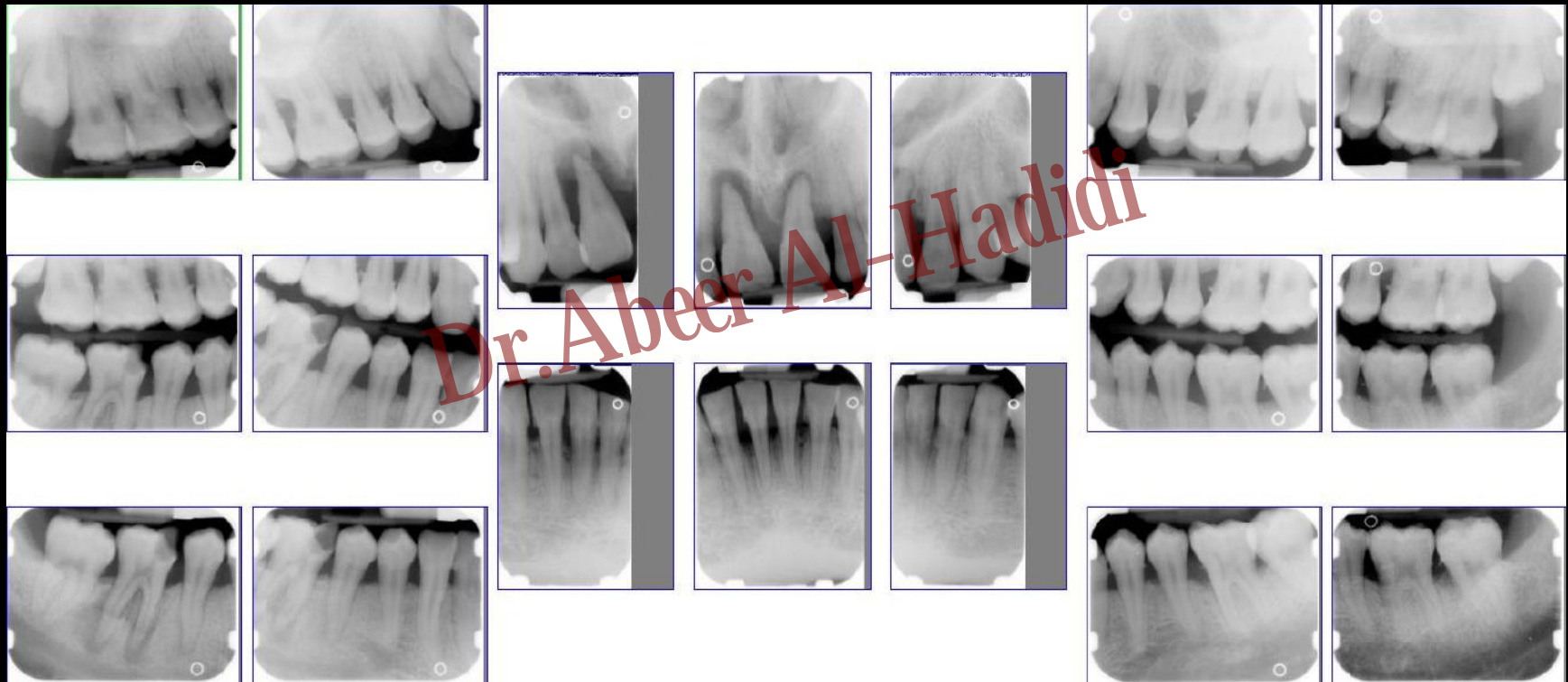
Case 3



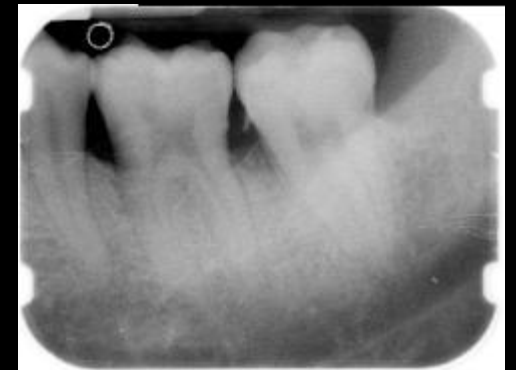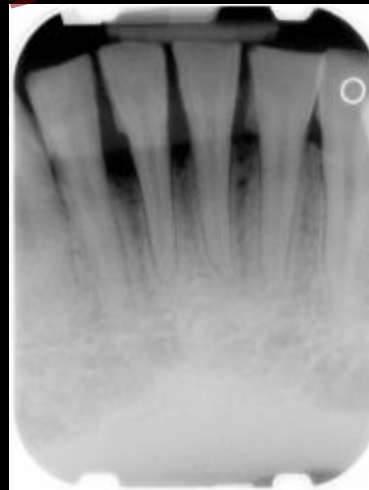
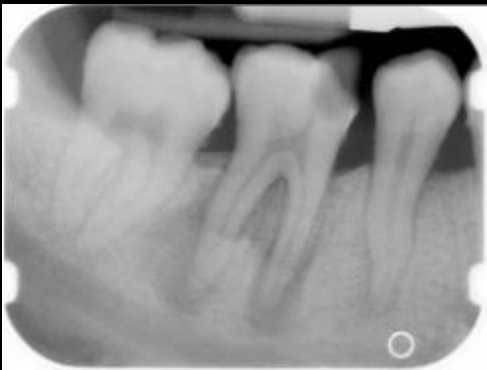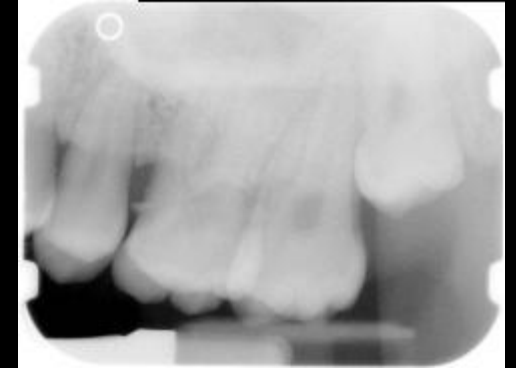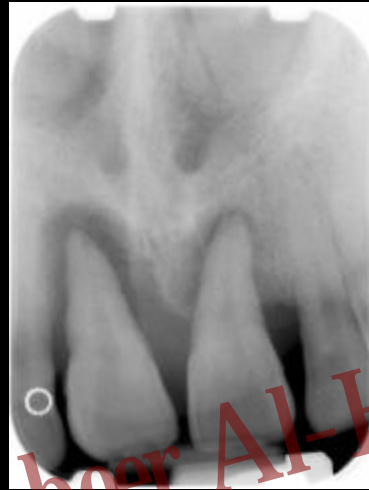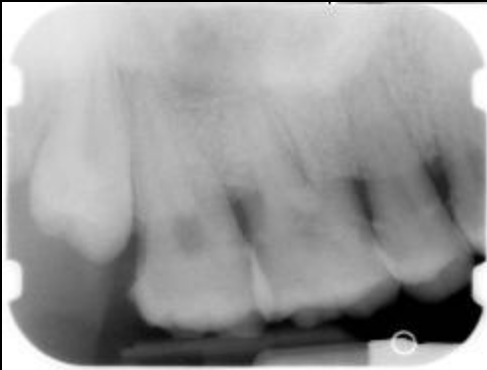Case 3
Pan 03-03-2011
Patient Reported to OS



Case 4

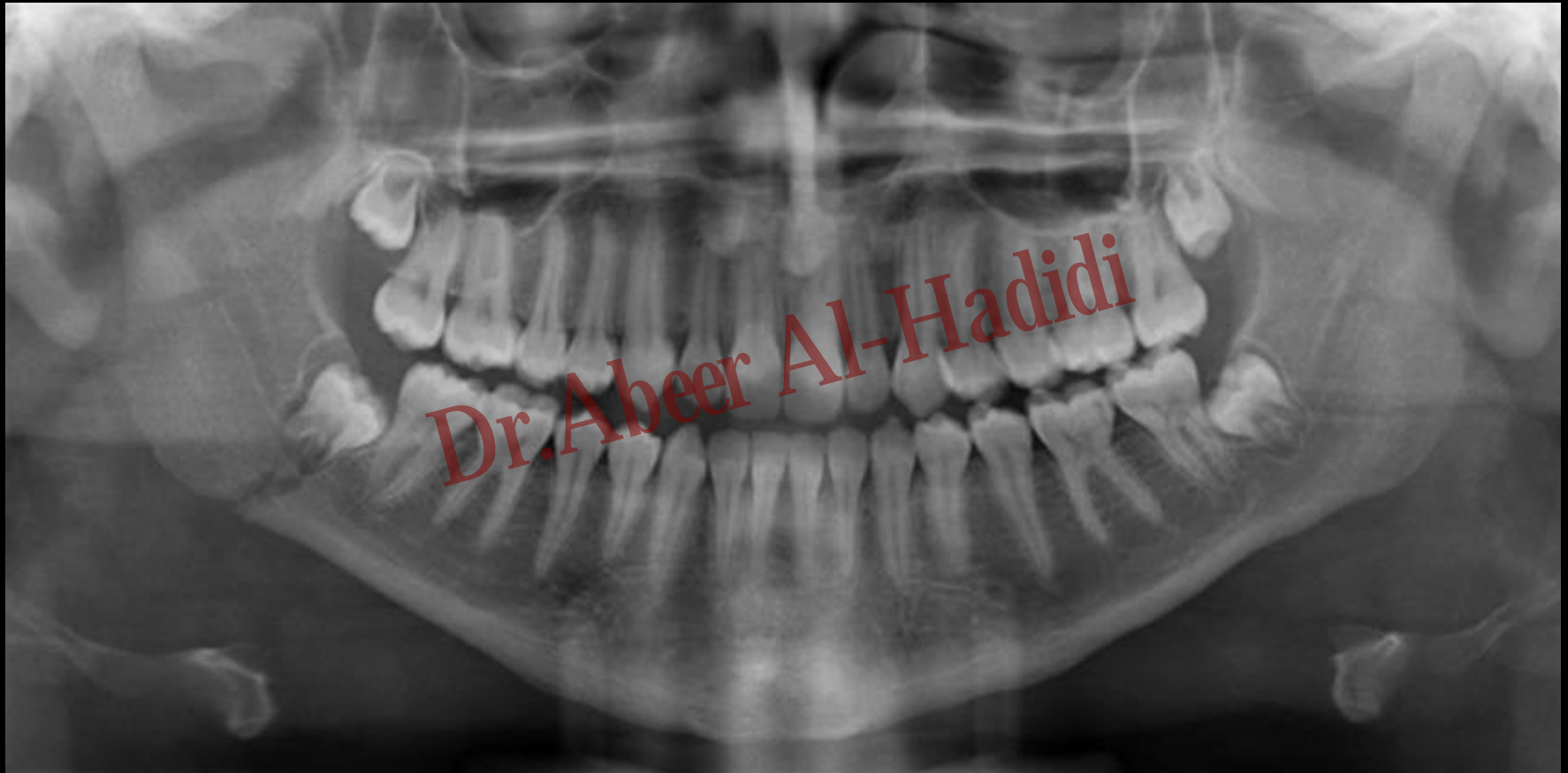

Case 4

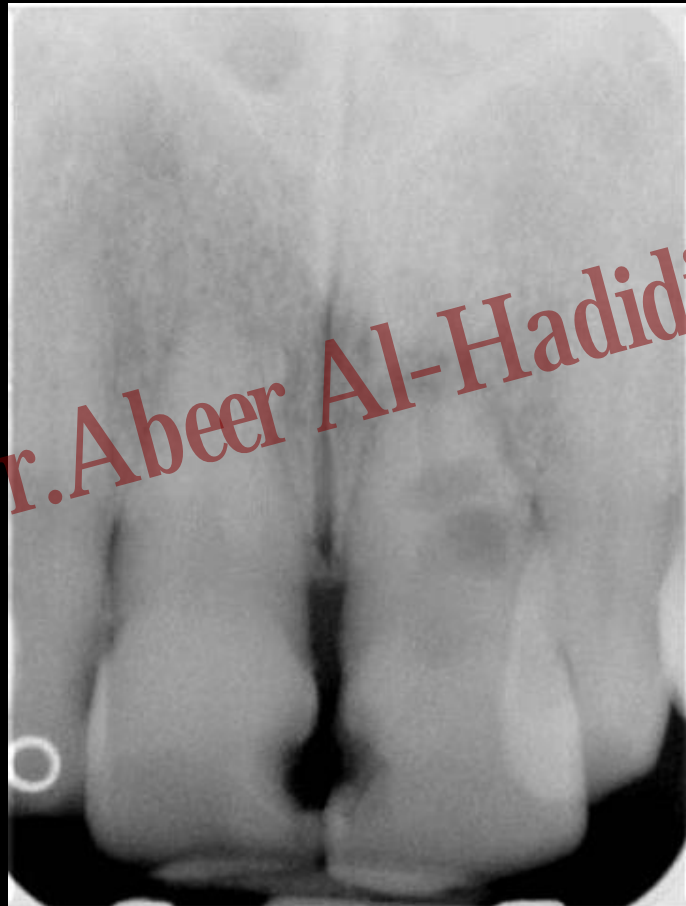


Dr. Abeer Al-Hadidi

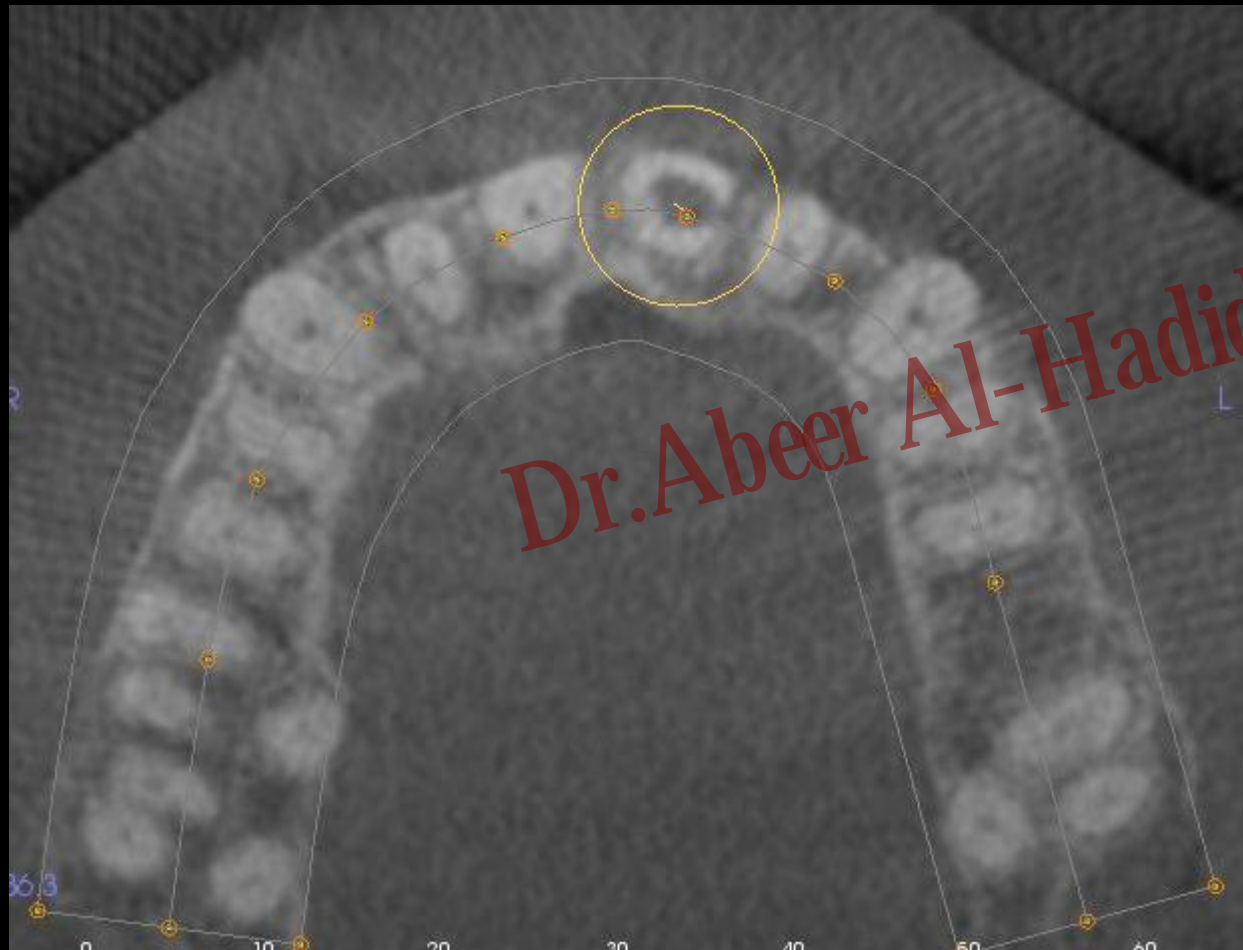
Case 5:



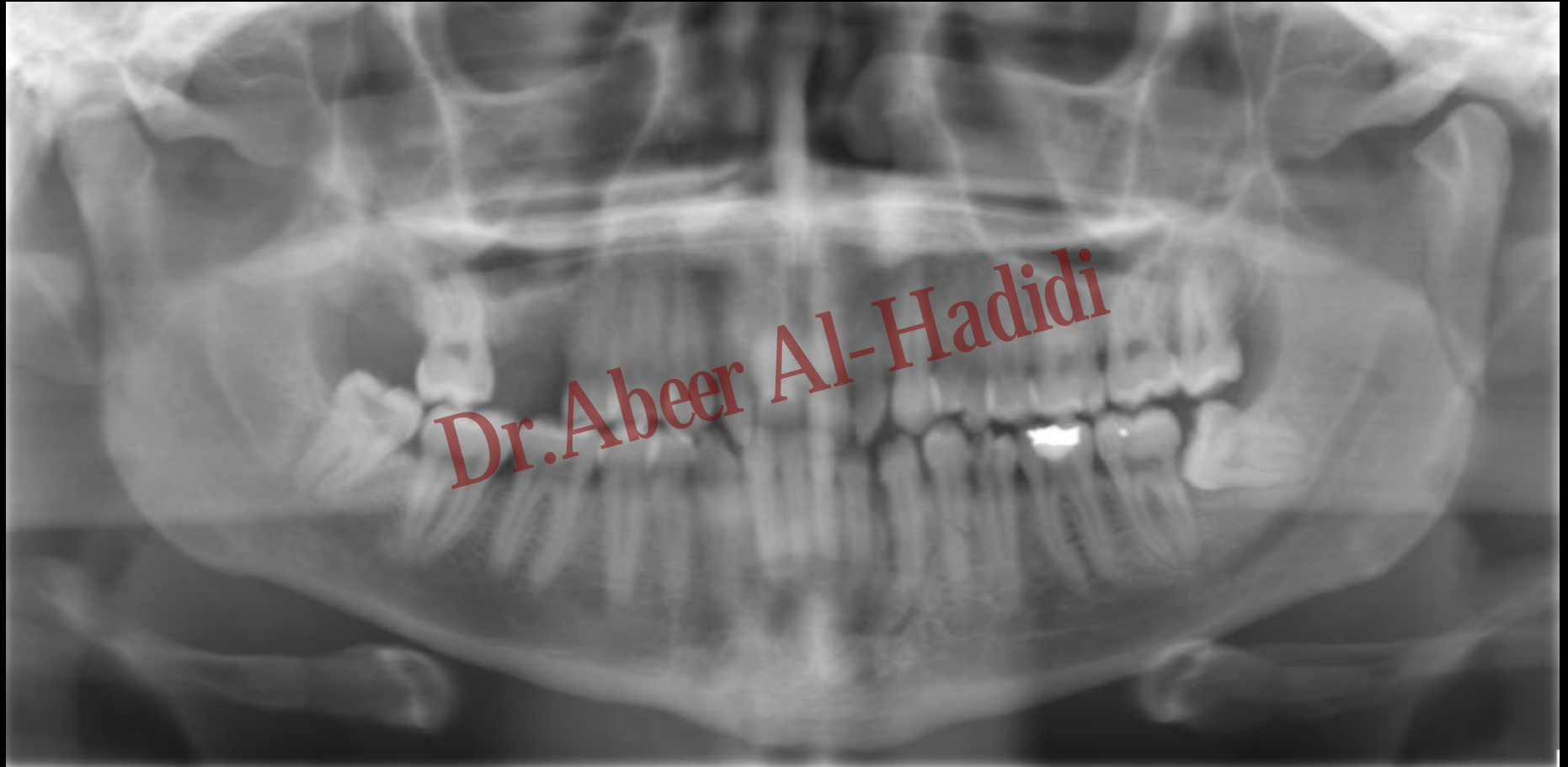Case 6



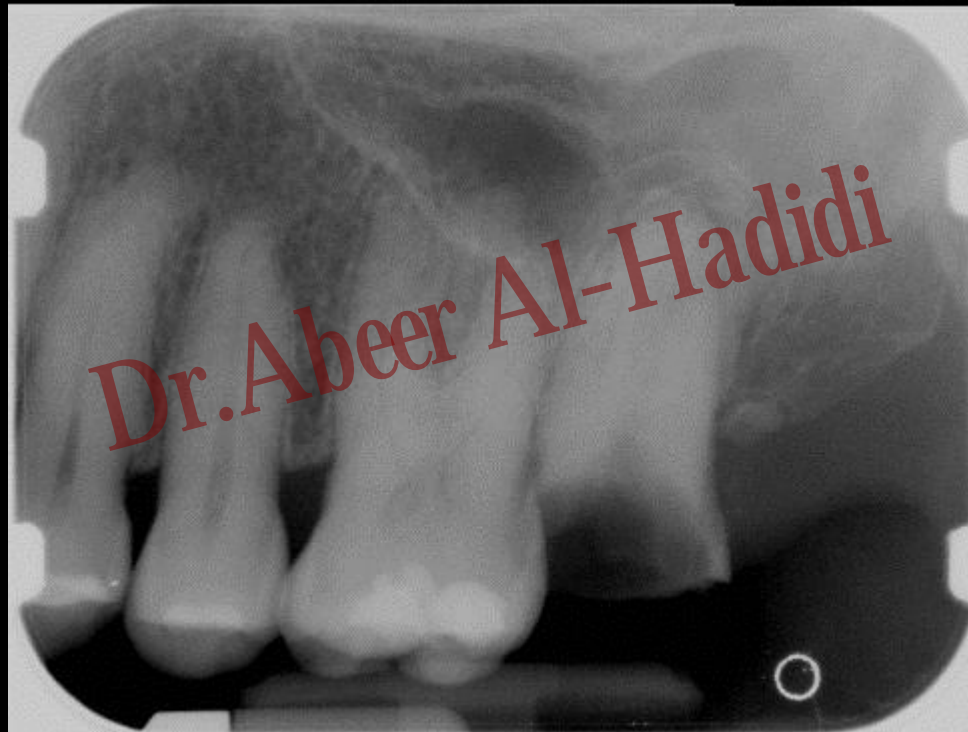Case 6



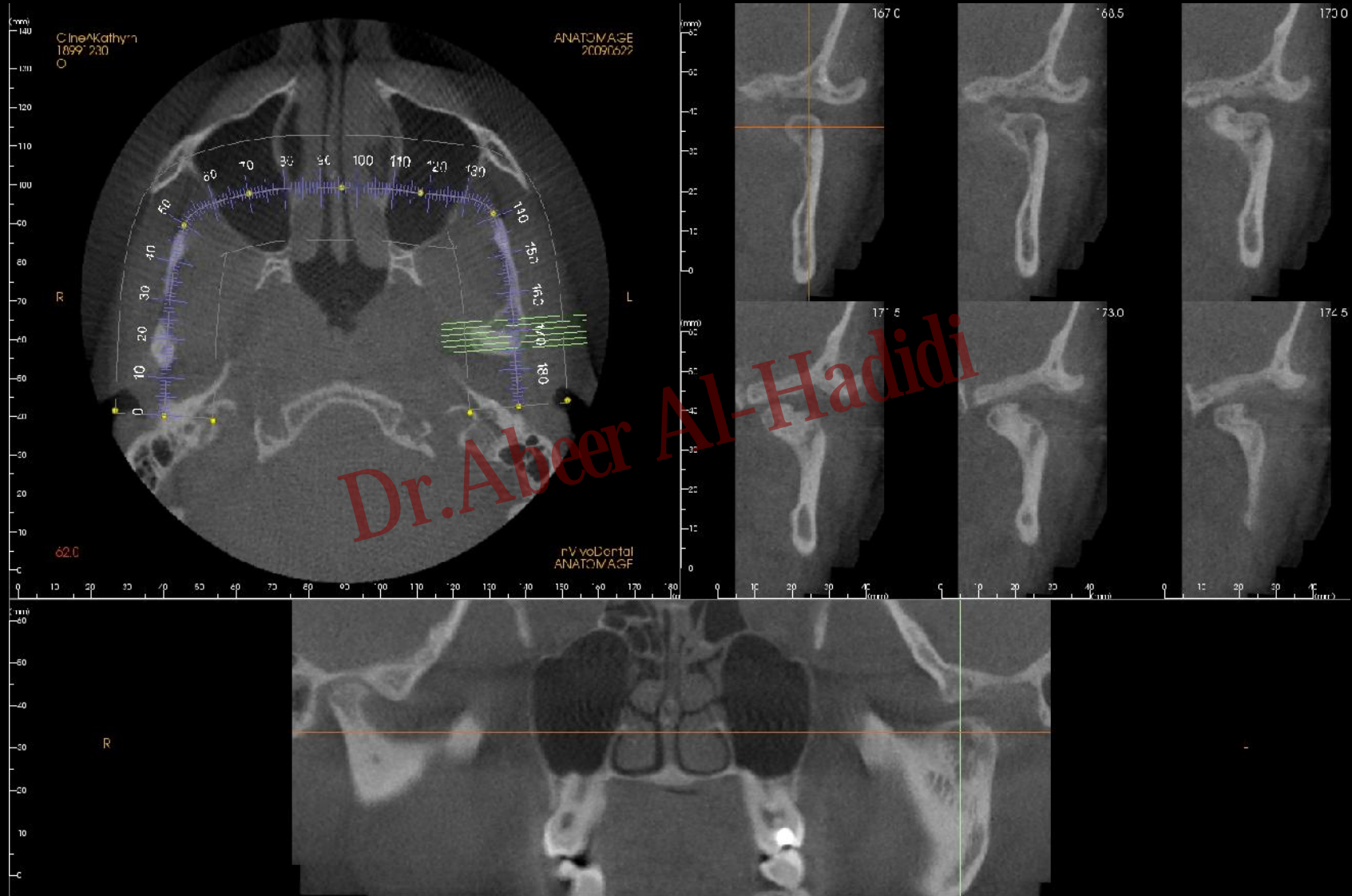
Case 7:



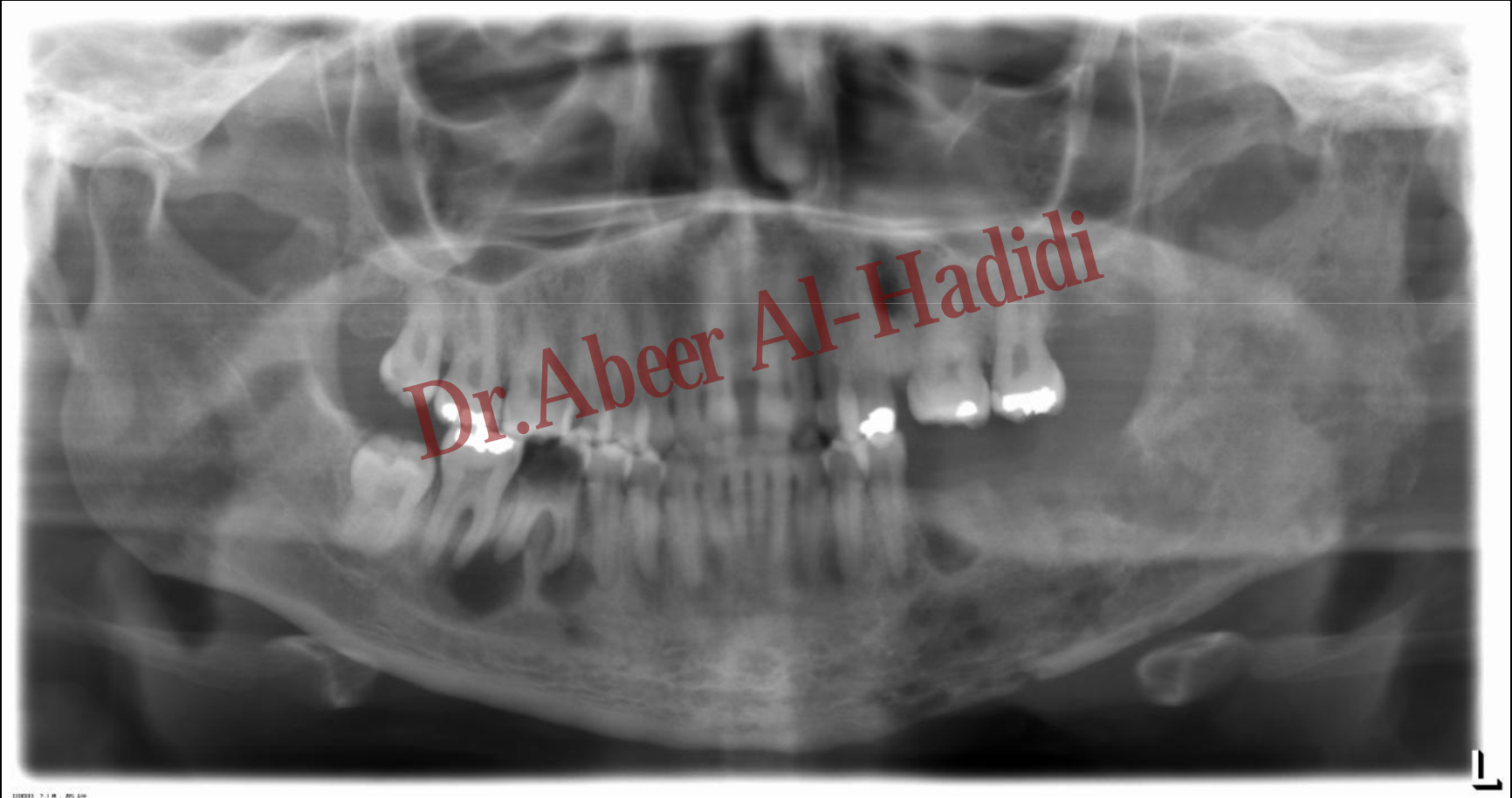Case 8



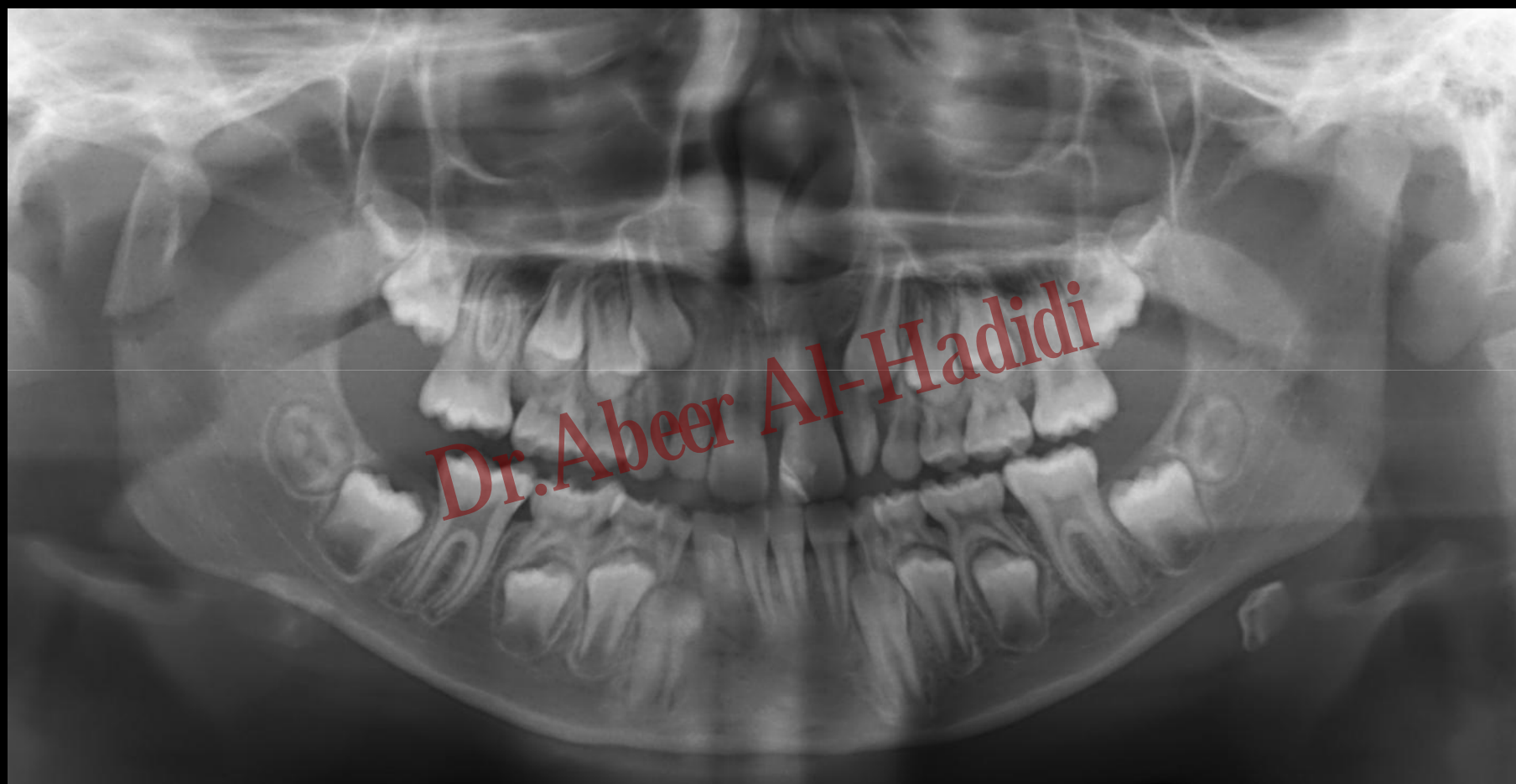
Case 9:

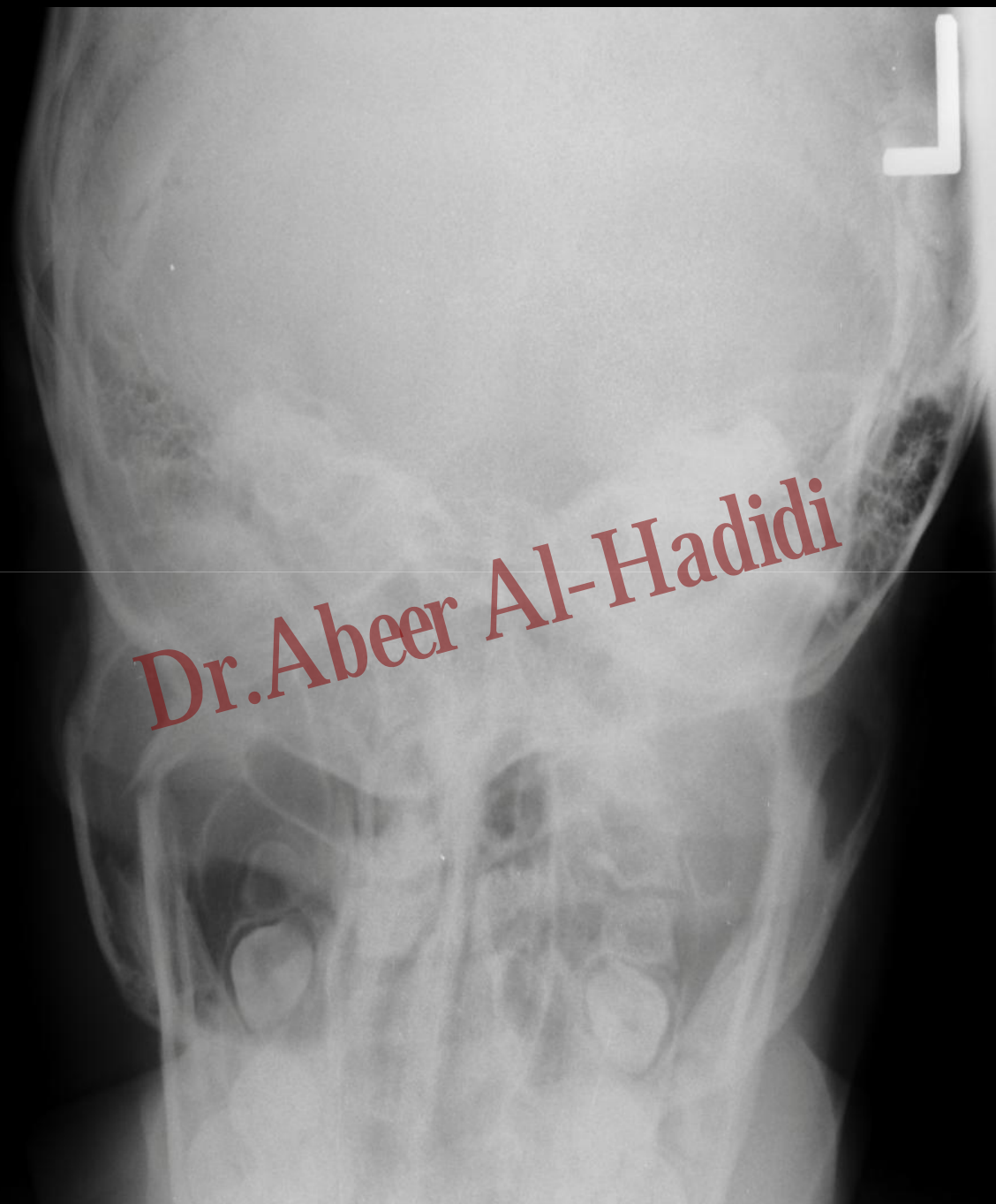


Case 10



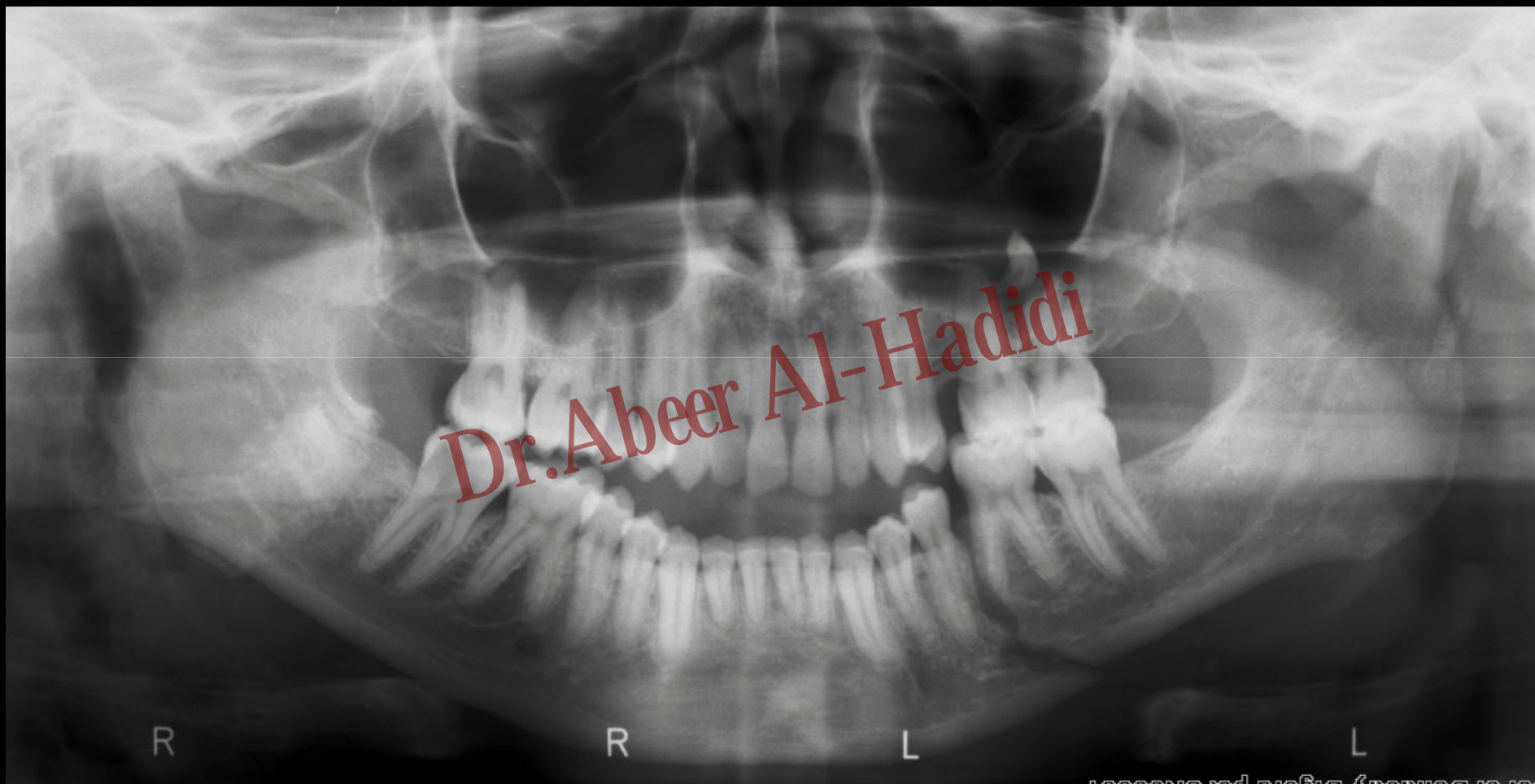Case 11:



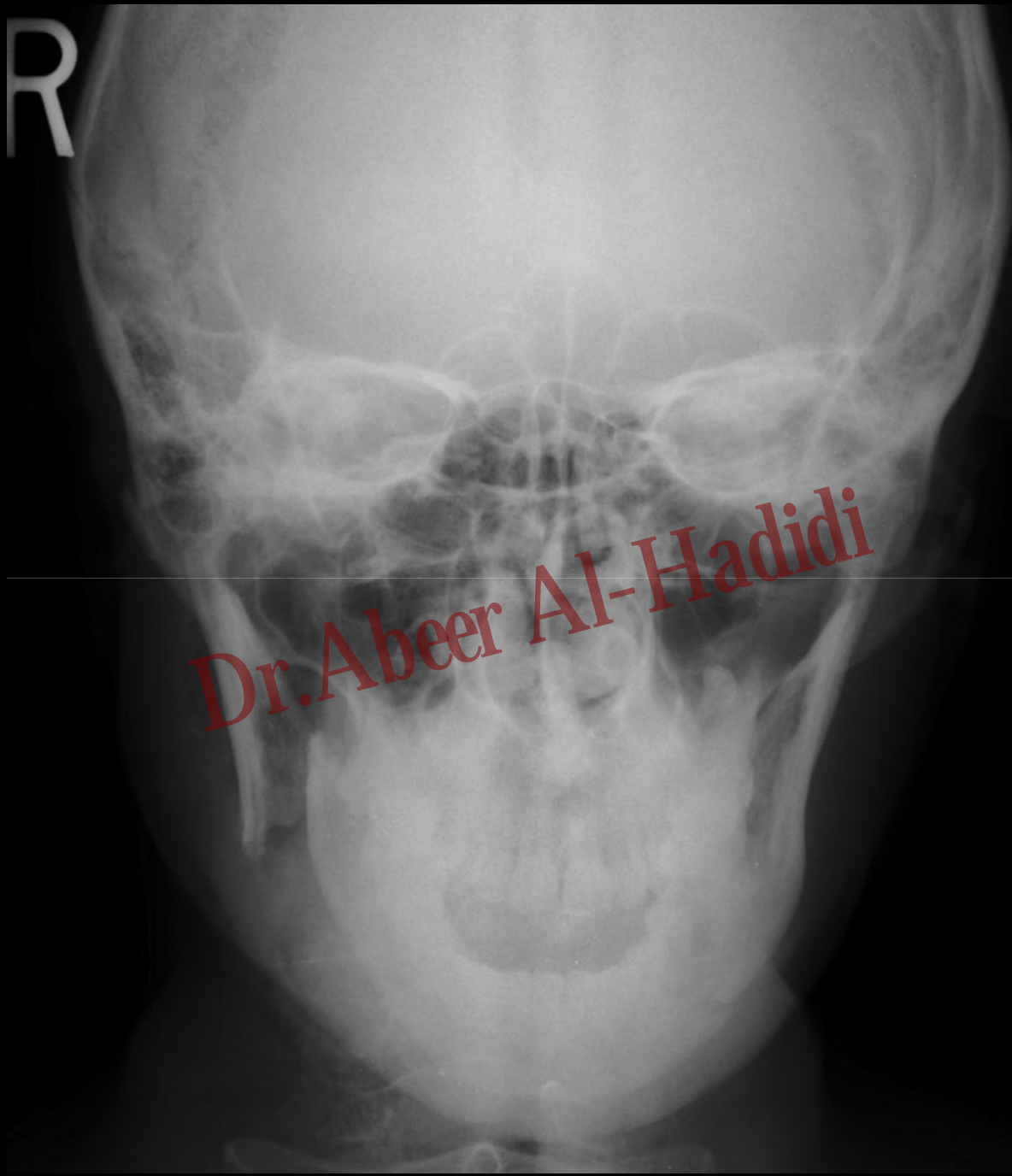

Dr. Abeer Al-Hadidi

Case 12:



R



Dr. Abeer Al-Hadidi