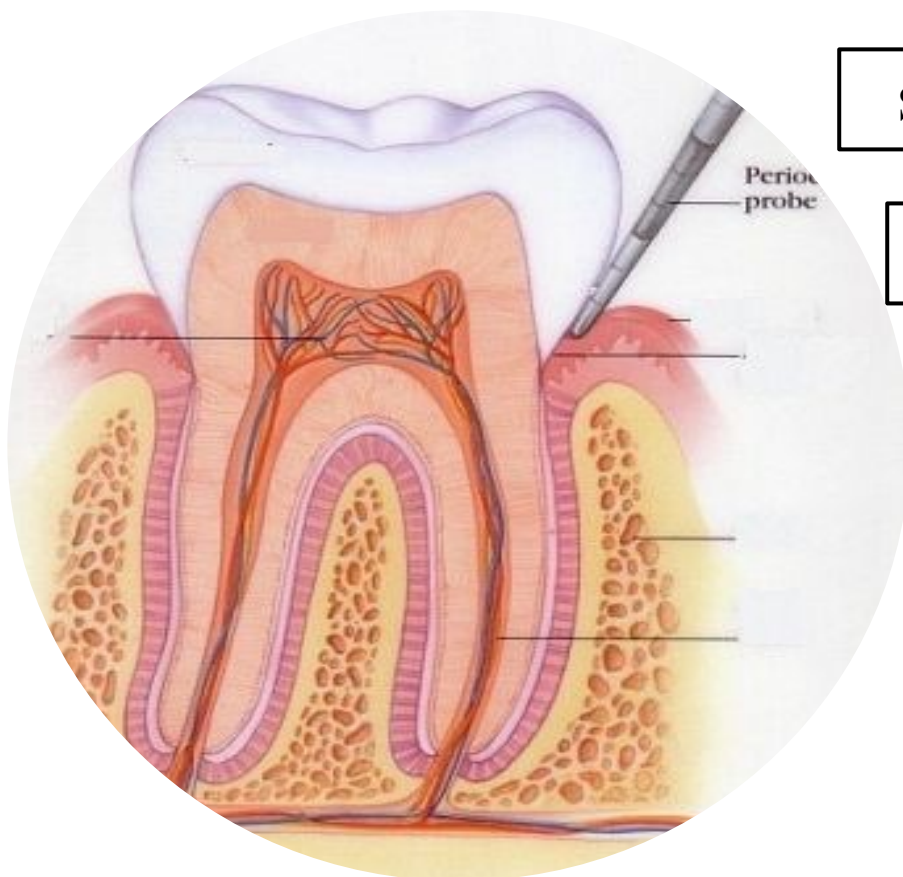




Periodontics II



Sheet ✓

Slide

Hand Out

| | |
|-------------|-------------------|
| Lecture No. | 6 |
| Date: | 15/11/2015 |
| Doctor: | Dr. Murad Shaqman |
| Done by: | Hind Alabbadi |

Designed by: Hind Alabbadi



Mucogingival surgery

We will talk about :

- 1) **Terminology**
- 2) **Indications**
- 3) **Etiology of recession** (recession is one of the mucogingival deformities)
- 4) **Techniques** to address mucogingival deformities:

There is a wide range of mucogingival deformities and different techniques for addressing mucogingival deformities

- **Terminology**

Mucogingival surgery: *surgical procedures for the correction of relationships between gingiva and oral mucous membranes.* (gingiva relating to the keratinized part, and oral mucous membranes relating to the non-keratinized part and these two meet at the mucogingival junction)

Mucogingival deformities could be:

- 1) involving attached gingiva
- 2) Gingival recession
- 3) shallow vestibule
- 4) or aberrant frenum.

More recently we are using the term **periodontal plastic surgery** and it's a more encompassing term (اوسع) and is defined as: *the surgical procedures performed to correct or eliminate anatomic, developmental, or traumatic deformities of the gingiva or alveolar mucosa.* It's not only for the deformities between gingival and mucous membranes, it became a much wider term to include a wide range of procedures such as:

- 1) *periodontal-prosthetic corrections:* such as gingivectomies
- 2) crown lengthening
- 3) *ridge augmentation:* when there is a ridge deficiency vertically or horizontally we augment it (we enlarge it).
- 4) esthetic surgical corrections
- 5) *coverage of the denuded (exposed, معرفة) root surface:* coverage of recession. This is the typical and the standard definition of mucogingival surgery.
- 6) Reconstruction of papillae.

- 7) Esthetic surgical correction around implants.
- 8) *Surgical exposure of unerupted teeth for orthodontics*: even the exposure of an impacted canine is considered as a periodontal plastic surgery; depending on how u do it, it might have negative esthetic effect if the exposure was done improperly.

All these procedures are periodontal plastic surgery.

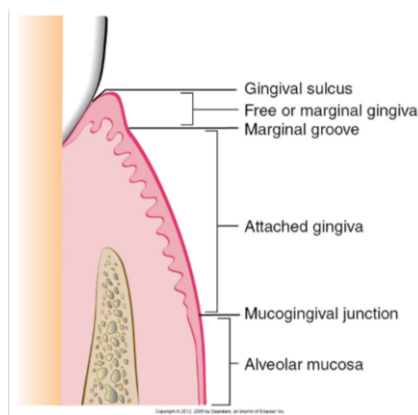
We will not talk about all of them. Crown lengthening and esthetic crown lengthening we will have lectures about them when talking about periodontal-restorative interrelationship. Ridge augmentation we won't talk about them; it's hard tissue augmentation and soft tissue augmentation.

- **Indications** of mucogingival surgery:

- 1) *Lack of attached gingiva*; whether having actual gingival recession or just narrow zone of attached gingiva. (this is discussed over the next few slides to explain how our understanding for this indication has changed over the past few decades)
- 2) Gingival recession (root coverage procedures)
- 3) *Shallow vestibule*
- 4) *Removal of frenum*.

Indication (1): The lack of attached gingiva:

:you all remember this diagram



Sometimes there is a very narrow zone of attached gingiva and this is seen mostly in canines and premolars. The widest zone of keratinized attached gingiva is usually in the upper lateral incisors

And when there is no attached gingiva this might be recession or anatomically there is an area of minimal zone of attached gingiva

Slide 8: this is recession and the mucosa is movable and it's keratinized mucosa but not attached. The attached gingiva is the part of gingiva from the depth of the sulcus to the mucogingival junction, while the part of gingiva above the

depth of the sulcus is the free or marginal gingiva and it's not attached. And in this case if we probe it and we have 2 mm probing depth we are passing the mucogingival junction

For a long period of time they thought that when there is no attached gingiva or minimum attached gingiva then this is a primer for attachment loss and recession and it will be more predisposed for inflammation, so they thought if there is no attached gingiva then you have to do graft to have attached gingiva to prevent inflammation and to prevent future recession.

The question is: *is there really a minimum amount of attached gingiva that is necessary for health.* So they made a long list of studies (animal studies, human studies) and they made 10 years follow up and they made a comparison between sites that they made a graft for and sites that they didn't make graft for. What they found that whether they made a graft or not as long as the patient has good and decent plaque control, the site can maintain a healthy periodontium even in the absence of attached gingiva

So there is **no really a minimum requirement of attached gingiva; what matters most is plaque control.** So a patient with a decent plaque control can maintain a healthy gingiva even in the absence of attached gingiva. This is a big indication that most of mucogingival surgeries are no longer valid. **The indication that was driving a lot of mucogingival surgeries (which is the absence of attached gingiva) is no longer valid**

In slide8: a student asked if this tooth with recession is mobile and the dr answered that this tooth is splinted with orthodontic permanent retainer, and the tooth lost bone around it only from the facial aspect but there is bone attachment all around the tooth even if there is no retainer this tooth most probably won't be mobile

The question now: *is it due to the absence of attached gingiva the recession happens or the recession itself results in the lack of attached gingiva.* Because when recession happens the first part to be lost is the keratinized part which is the attached gingiva so which one is first the recession or the absence of attached gingiva. What causes the other? *Which comes first?* Most likely it's recession that leads to no attached gingiva

Does that mean if we saw an area with no attached gingiva then there is no need to interfere? The idea is that there is no general rule that there should be an attached gingiva but if there is a situation where there is a lack of attached gingiva and there is obvious pathological sequels (consequences for the lack of attached gingiva) then you might have to intervene

Slide 12: what happens when you don't have attached gingiva, in many cases, plaque control becomes difficult. The indication here to do something is not because there is no attached gingiva, it's rather because the patient can't perform adequate plaque control. If the patient wants to brush, it will be very painful and very uncomfortable

- **So why do we sometimes correct the lack of attached gingiva?:**

- 1) *To facilitate good plaque control;* the patient cannot perform good plaque control.
- 2) *To improve esthetics;* because many times when there is mucosal margin without gingival margin the color of the mucosa will be more reddish and sometimes it's not esthetic.
- 3) *To reduce inflammation around restored teeth.* The only indication when there is no minimum of at least 2 mm of attached gingiva that you would do a surgery to correct it when there is a restorative margin right there where there is a mucosal margin. (when there is no attached gingiva and there is good plaque control you don't have to graft it, but if there is no attached gingiva and there is a crown or a restoration then you should graft). Because there are studies showing that when there is a crown there will be higher plaque accumulation and higher inflammatory status so you want to improve the quality of the tissues.
- 4) *To have a gingival margin that binds better around teeth and implants.* Mucosa is movable it's not tightly bound to the underlying bone or tooth, while gingiva is not only bound to the bone but also to

the tooth with dentogingival fibers (fibers that bind gingiva to the tooth). So when there is mucosa around the tooth or implant there would be no good binding tissue around and that is another indication for correction of lack of attached gingiva.

So the lack of attached gingiva doesn't necessitate inflammation and recession and thus doesn't necessitate the need for surgery.

So there is some degree of clinical judgment so one periodontist may say there is a need for a graft to increase the zone of attached gingiva while another periodontist may say there is no need for graft for the same case.

Slide 14: this is an example how the patient can't perform good plaque control; very tender and very uncomfortable. So if we want to do surgery we will do it to facilitate plaque control and to correct the recession.

Slide 15: this is an example of an esthetic complain from the patient. This is a premolar by the way; the patient had orthodontic treatment and they put the premolar in the place of the canine.

Slide 16: this is a case where there is almost no attached gingiva around the tooth. (barely there is 0.5 mm of attached gingiva). And the tooth is going to receive a crown so we will do a free graft. After the graft the picture is showing a white zone of keratinized gingiva which will facilitate plaque control around that crown. Also before the graft the fold of the vestibule was almost at the crown margin and after the graft there is vestibule deepening.

Slide 17: this is an example when there is no bound and tight zone of gingiva around implants and teeth. This is an overdenture case, and there are implants to support the overdenture. And all mucosa around the implants are unattached, so if you pull the patient's lip the mucosa will move exposing the implants, so there will be poor hygiene there. That's why in most cases when you want to do implants for future overdenture you should check the amount of attached gingiva; because after teeth extraction the amount of attached gingiva shrinks. So if a patient came and his teeth was extracted 20-25 years ago he will have very narrow zone of attached gingiva and that's not gonna be enough, so a lot of these cases you have to graft around the implants to have zone of keratinized tissue around those implants.

Summary:

- The lack of attached gingiva or the presence of a narrow zone of attached gingiva WAS considered an indication for free gingival graft or surgery to increase the width of the attached gingiva. This was due to:
 - The clinical observation that areas with minimal or no attached gingiva had more redness and inflammation.
 - A belief that grafting would reduce the risk of recession or further recession.
- Based on many human and animal studies, this was later shown to be not true, meaning that lack of attached gingiva did not result in greater inflammation and grafting did not make a big difference:
 - although areas with no attached gingiva might look more inflamed clinically, histological evaluation has shown that—> the size and extension of the inflammatory cell infiltrate (ICT) (which is considered a measure of the degree of inflammation) in areas with “adequate” attached gingiva or without attached gingiva is the same considering similar plaque irritation.
 - longitudinal human studies in which grafting to increase width of attached gingiva was done on one side of the mouth while other side left without grafting showed that there were no differences, and non-grafted sites performed similarly to grafted sites.

Summary:

- So... indication for grafting to increase width of attached gingiva is performed in cases as per slide 13.
- **You might notice that i included gingival recession as one of the indications of mucogingival surgery... to reduce confusion. historically, root coverage for treatment of recession was not a major indication! and classical indications for soft tissue grafting were (lack of attached gingiva, vestibule deepening and aberrant frenum). recession is discussed as part of the lack of attached gingiva indication because it is related to lack of attached gingiva .. how? because recession was historically thought to be caused by lack of attached gingiva (hence all the previous discussion regarding the impact of lack of attached gingiva) and because recession results in reduced or lack of attached gingiva.**

Indication (2): **Gingival recession**

- Now let's talk about gingival recession (will continue talking about gingival recession in the next lecture)

We will talk about:

- **Definition**
- **Etiology**
- **Classification**
- **Definition:** *Recession is when the location of the marginal periodontal tissues (the gingival margin) is apical to the cementoenamel junction.*

What does that mean? Which part is going to be visible? The cementoenamel junction and the root are visible; the root is exposed. If the root is not exposed it's not gingival recession. Because sometimes specially in lower anteriors even in upper anteriors ,the gingival margin of adjacent teeth is too coronal, you think there is recession but the root is not exposed and the gingival margin is where it supposed to be but relative to adjacent teeth it looks like as if the gingiva is receded. This is mostly seen in mixed dentition especially when there is crowding and the gingival margin is not even one tooth is directed to the outside and another one is directed to the inside, the tooth that is directed to the inside (lingually incline) will have a more coronal gingival margin, while the tooth that is more buccally inclined will have more apical gingival margin.

3 main causes of gingival recession:

- .A\ Mechanical truma
- .B\ Localized plaque induced lesion
- C\ generalized destructive periodontal disease

A\ Mechanical trauma:

1. **Aggressive toothbrushing.**
2. **Iatrogenic: induced by dentist or dental professional: finishing of class V restoration.**
3. **Factitious: self induced: paper clip or pen cap or else.**
4. **Piercing in the oral or mucosal tissues: tongue or lip piercing.**

Regarding Occlusal interferences or malocclusion or bruxism you should know that it's per say does Not cause recession. Only actual physical trauma due to occlusion might cause recession for eg. deep bite where the incisal edges are physically traumatizing the gingival.

Regarding aggressive tooth brushing **Why aggressive tooth brushing might cause recession in some pt's and not others?**

It depends on the **predisposing factors**:

- ① **Thin biotype.**
- ② **Prominent roots**
- ③ **Orthodontic therapy**
- ④ **High frenal attachment**

Thin biotype: it is a description of certain anatomical feature that is percent in the pt's gingival ①

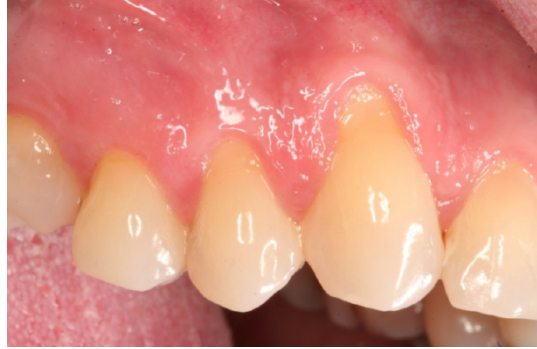| Thin biotype | Thick biotype |
|---|---|
| -More susceptible to recession. - Very thin buccal bone in which if you rise a flap you will see fenestration, no bone (the soft tissue is attached directly to the root in the areas of dehiscence or fenestrations). -Long cylindrical teeth with triangular taper. -Highly scalloped gingival margin. | More resistant to recession - -Thick buccal bone. -Square teeth. -Average or flat scalloped gingival margin |

- ② **Prominent roots**
- ③ **Orthodontic therapy**

A Slide shows a tooth with prominent root for a pt with history of ortho tx, it's the only tooth that has recession because during ortho tx there was no good control on the amount of tongue forces and with time the root become prominent with recession.

④ **High frenal attachment** : insertion of frenum to the vestibule instead to the gingival margin and it's one of predisposing factor due to pulling action. So the only time I suspected that the gingival recession is due to the frenum is where the frenum is attached to gingival margin of the tooth.

Slide 20: this is a case of recession due to mechanical trauma, here the probing depth =2-3mm with bleeding. Why the canine in this case is more predisposed and more affected? Because one of the predisposing factor is prominent root of canine or may be due to thin biotype.



B\ Localized plaque induced lesion in isolated tooth (or teeth):

- Not mechanical trauma it's plaque induced.

-Remember that in case of aggressive tooth brushing it will affect multiple teeth, but more importantly teeth are plaque free and signs of tooth wear might exist..

Slide 21: this is a case of recession due to localize plaque induced lesion, The first thing to do is scaling and root planing, improve plaque control, before planning soft tissue grafting or root coverage procedures.

C\ generalized destructive periodontal disease:

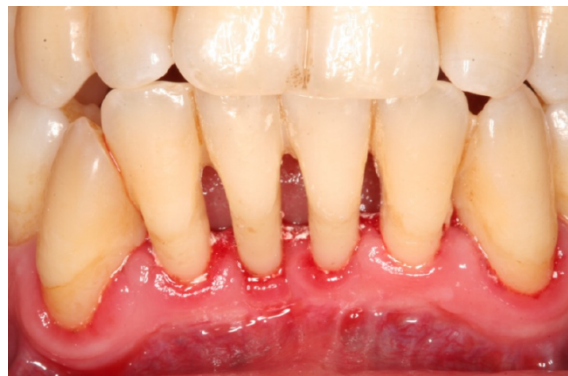- For example in Periodontitis case.

-Here the recession affects also the proximal surfaces of the teeth (recession all around) because in periodontitis it starts proximally.

-Recession is attachment loss because the pt had attachment then it recceed, so he lost the attachment (so it's attachment loss).

-One of the causes of gingival recession is periodontitis, But it's not the only cause, so if you see a pt. with recession **don't** diagnose it directly as periodontitis.

Slide 23: this is a case of periodontitis, note that the recession involves interproximal areas.



Classification of gingival recession:

| | | |
|-----------------------|--|--|
| Miller 1 class | Recession does not cross the mucogingival junction & no proximal bone loss (no attachment loss) | |
| Miller class 2 | Recession goes pass the mucogingival junction & no proximal bone loss (attachment loss) | |
| Miller class 3 | Proximal bone loss (attachment loss), But the level of proximal attachment loss is still <u>coronal</u> to the buccal recession. | |
| Miller class 4 | Proximal bone loss (attachment loss), But the level of proximal attachment loss is <u>at or apical</u> to the buccal recession. | |

_Some literature reported that when the tooth is too prominent even if no proximal attachment loss it is miller 3 why? Because Miler Classification help us in prediction of the successful of the tx of gingival recession and if grafting is a good tx chose or not

(An example of **Poor prognosis of root coverage** is in periodontitis case. (next lecture _

Indication for mucogingival surgery

Indication (3):

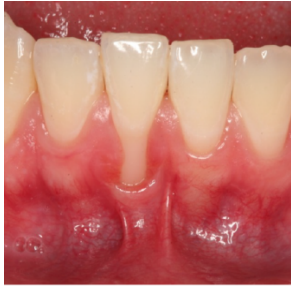
- Shallow vestibule:
 - Impede proper plaque control
 - interfere with prosthesis

The most predictable way to deepen the vestibule is with a free gingival graft from the palate because some technique with incisions is not predictable and relapse may occur.

Indication (4):

- Aberrant frenum
 - Interfere with the gingival margin
 - Interfere with prosthesis

Slide 34 : a case where the frenum attachment is on the gingival margin and this could be predisposing factor for gingival recession & may prophylactically recommend to remove it.



Now Surgical technique: (For next lecture)

1) Augmentation apical to the gingival margin:

To increase the width of keratinized gingival, the pt. has recession and he can't perform good oral hygiene or he has shallow vestibule or when I will do crown for him.

2) Augment coronal to the gingival margin:

To achieve root coverage.



Keep Calm and Enjoy your Senior Year :P, many thanks for Lyn El-Smadi.