

The Space-Closure Alternative for Missing Maxillary Lateral Incisors: An Update

MARCO ROSA, MD, DDS, DO
 BJÖRN U. ZACHRISSON, DDS, MSD, PHD

Treatment planning for patients with missing maxillary lateral incisors traditionally includes either space closure^{1,2} or space reopening and insertion of implants.^{2,3} Some common objections to orthodontic space closure are that the treatment outcome may not look “natural”, that the functional occlusion is compromised, and that retention of the treatment result is difficult.

Although it may appear preferable esthetically and functionally to create space for replacement of the missing lateral incisor with a single-tooth implant^{4,5} or resin-bonded bridge,⁶ and while high survival rates for implant-supported porcelain crowns can be expected, long-term biological complications are frequent⁷⁻¹⁹ (Table 1). At present, it is not possible to predict when such unesthetic changes will appear. Progressive infra-occlusion may occur due to the continuous erup-

tion of adjacent teeth (Fig. 1), even when an implant is placed in a mature adult.^{8,9,13-15} Obviously, an osseointegrated implant crown will not undergo the normal uprighting of upper and lower incisors that occurs from adolescence to adulthood,^{16,17} which means the implant crown will become more infraoccluded and protrusive in appearance over time.¹³ Furthermore, blue coloring of the labial gingiva has been reported above more than 50% of single-implant crowns at four-year follow-ups.¹² Such darkening is caused by the resorption of endosteally derived bone, which is more porous and more prone to resorption than periosteal bone. Abutment exposure due to retraction of the labial gingiva is another complication,¹³ possibly caused by toothbrushing damage and other factors. The frequent lack of complete gingival papillary fill around implant crowns^{12,18} may also have esthetic

TABLE 1
ADVANTAGES AND COMPLICATIONS OF IMPLANT SUBSTITUTION FOR MISSING MAXILLARY LATERAL INCISORS

Advantages of Single Implants	Common Complications of Single Implants
<ul style="list-style-type: none"> • Optimal posterior occlusion • Satisfactory short-term esthetics • Comparatively short and simple orthodontic treatment • No need for build-ups of neighboring teeth • Long-term implant osseointegration 	<ul style="list-style-type: none"> • Progressive infraocclusion (even in mature adults) • Lack of uprighting compared to natural incisors • No means of orthodontic adjustment • Blue coloring of labial gingiva • Visibility of metal or porcelain abutment over time • Interdental recession (particularly distal papilla) • Difficulty of making natural-looking porcelain crown • No long-term observations (>10-15 years)

Dr. Rosa is a Professor of Orthodontics, Insubria University, Varese, Italy, and in the private practice of orthodontics at Piazza della Mostra, 19, 38122 Trento, Italy; e-mail: marco@marcorosa.it. Dr. Zachrisson is an Associate Editor of the *Journal of Clinical Orthodontics*; a Professor Emeritus, Department of Orthodontics, University of Oslo, Norway; and in the private practice of orthodontics in Oslo.



Dr. Rosa



Dr. Zachrisson

consequences. Finally, it should be remarked that it is not easy to make implant crowns that blend perfectly with the neighboring teeth. Indeed, Tuverson remarked that the color of the canine usually comes closer to that of adjacent teeth than to the color of porcelain crowns.¹⁹

Our appreciation of the space-closure alternative has increased during the last decade as we have tried to improve our results by combining carefully detailed orthodontic treatment with techniques from esthetic dentistry^{20,21} (Fig. 2). Used

together, these methods can provide the improvements needed to approach the appearance of a natural intact dentition and thus make orthodontic space closure a more attractive treatment alternative, especially in young patients and in those who show a substantial amount of gingiva when smiling. A biological, esthetic, and stable result using natural teeth in the anterior maxilla appears more appealing to us than the insertion of foreign bodies that will remain in place throughout the patient's lifetime.

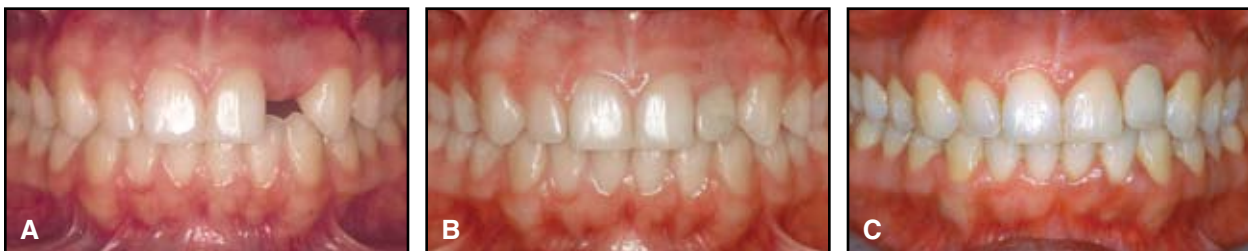

Fig. 1 A. 20-year-old female patient with upper lateral incisor space reopened for implant placement. B. Temporary crown on implant looks ideal at end of orthodontic treatment. C. Only five years later, infraocclusion of implant restoration is evident due to continuous eruption of adjacent teeth.

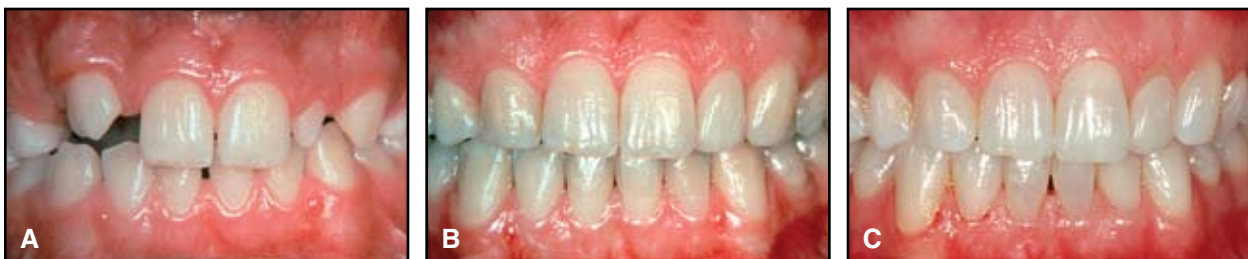

Fig. 2 A. Adolescent female patient with maxillary right lateral incisor agenesis and peg-shaped left lateral incisor (same case as shown in Figure 4 of previous article²⁰). B. Right canine extruded during orthodontic space-closure treatment and recontoured solely by grinding; porcelain laminate veneer crown placed over peg-shaped lateral. C. Natural gingival and incisal contours maintained 19 years after treatment, with no sign of infraocclusion; gingivae show normal pink color, stippling, and intact interdental papillae.

We have also recommended that clinicians should evaluate and eventually restore the central incisors in many patients with missing lateral incisors.²¹ Widening and lengthening the central incisors allows such patients to optimally display their dentition during speech and smiling.

We have achieved satisfactory, stable outcomes over many years of using canine substitution for missing lateral incisors.^{20,21} In some pa-

tients, however, the resulting dentitions did not appear entirely natural; in others, the composite resin build-ups²⁰ needed more maintenance than expected. In this article, we have selected two difficult and challenging patients from Dr. Rosa's pool of recently treated maxillary lateral agenesis cases to demonstrate further improvements and provide new clinical guidelines for the space-closure alternative.

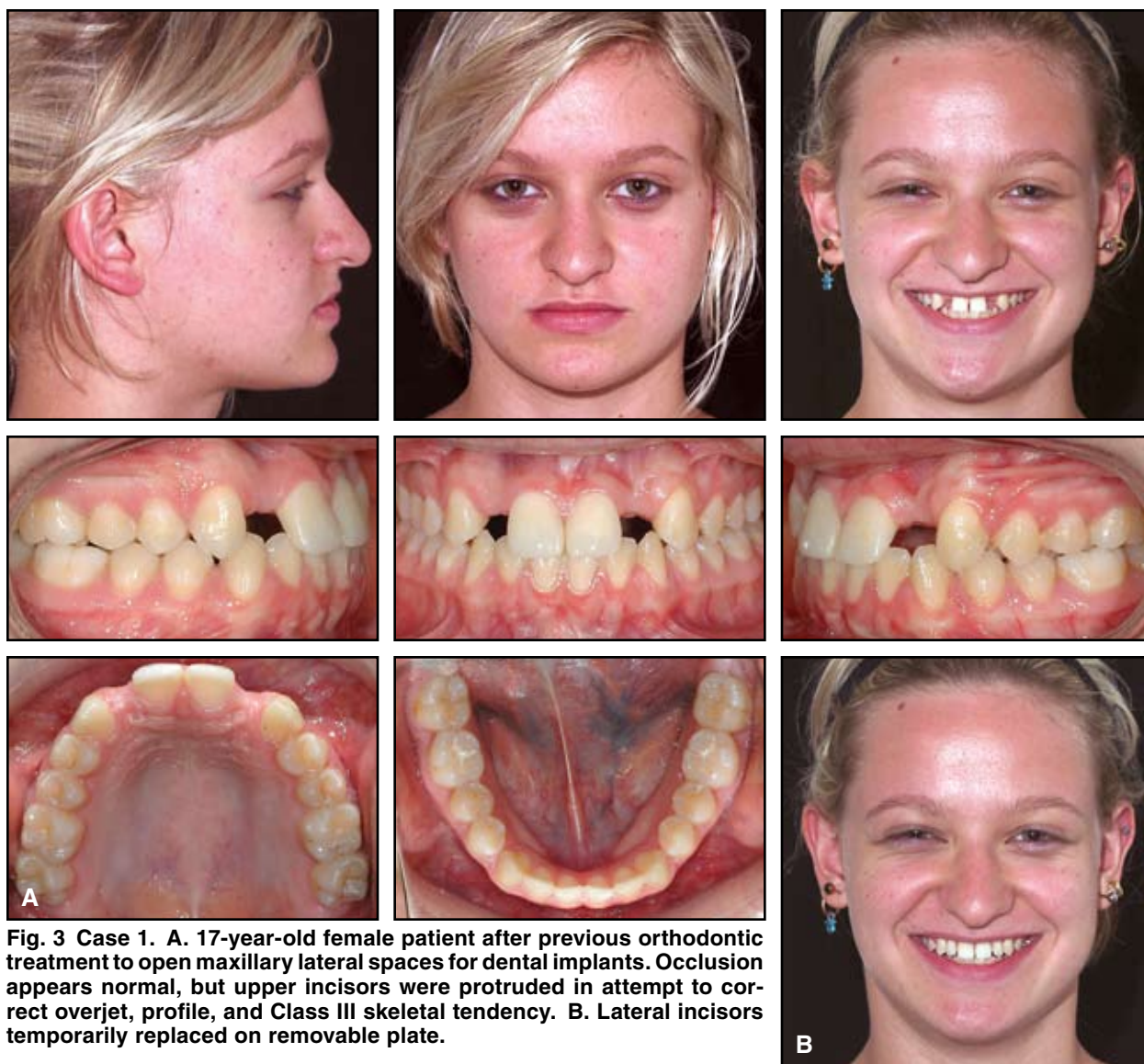

Fig. 3 Case 1. A. 17-year-old female patient after previous orthodontic treatment to open maxillary lateral spaces for dental implants. Occlusion appears normal, but upper incisors were protruded in attempt to correct overjet, profile, and Class III skeletal tendency. **B.** Lateral incisors temporarily replaced on removable plate.

Case 1

A 17-year-old female presented with a Class I malocclusion and a hypodivergent Class III skeletal tendency due to a retrognathic, short maxilla (Fig. 3). The mandibular arch was normally shaped, with minor crowding. Because of the Class III malocclusion and narrow maxilla, a previous orthodontist had decided to open space and improve the profile by means of maxillary expansion and upper incisor proclination. The patient was awaiting implant substitution “at the end of growth”, but was not fully satisfied with the interim result.

Our advice was not to refine the initial treatment, but to start over with different goals:

- Space closure and retraction of the upper incisors.
- Surgical maxillary advancement, involving vertical augmentation with clockwise rotation of the occlusal plane, to increase the amount of maxillary incisor display in smiling and the overall vertical dimension of the face.
- Cosmetic and functional composite restoration of the six anterior teeth at the end of orthodontic treatment.
- Porcelain laminate veneers to replace the composite restorations at the end of growth.

We believed such a treatment approach could achieve not only an optimal occlusion, but a well-balanced, natural smile that would be stable over the long term.

At the beginning of orthodontic treatment, the upper canines were reshaped mesiodistally by stripping, and their buccal surfaces were flattened. Maxillary space closure was obtained in six months using fixed appliances supported by Class II elastics (Fig. 4). It is of considerable interest that after the space closure, the profile did not worsen from a clinical point of view, despite the 7mm retraction of the upper incisors. On the other hand, it is not likely that a significant improvement in the profile could have been achieved by moving the teeth in the opposite direction (by proclining the upper incisors), considering the narrow, retrognathic maxilla of this hypodivergent patient.

A maxillary vertical augmentation with mesial displacement and rotation of the palatal and occlusal planes was performed by Dr. Mirco Raffaini, Parma, Italy. The lower third molars were extracted during the surgery.

Orthodontic finishing lasted 11 months. Moderate stripping was performed on the lower anterior teeth during this stage. The gingival shape and contour and the smile line were corrected by premolar intrusion and canine extrusion with torque

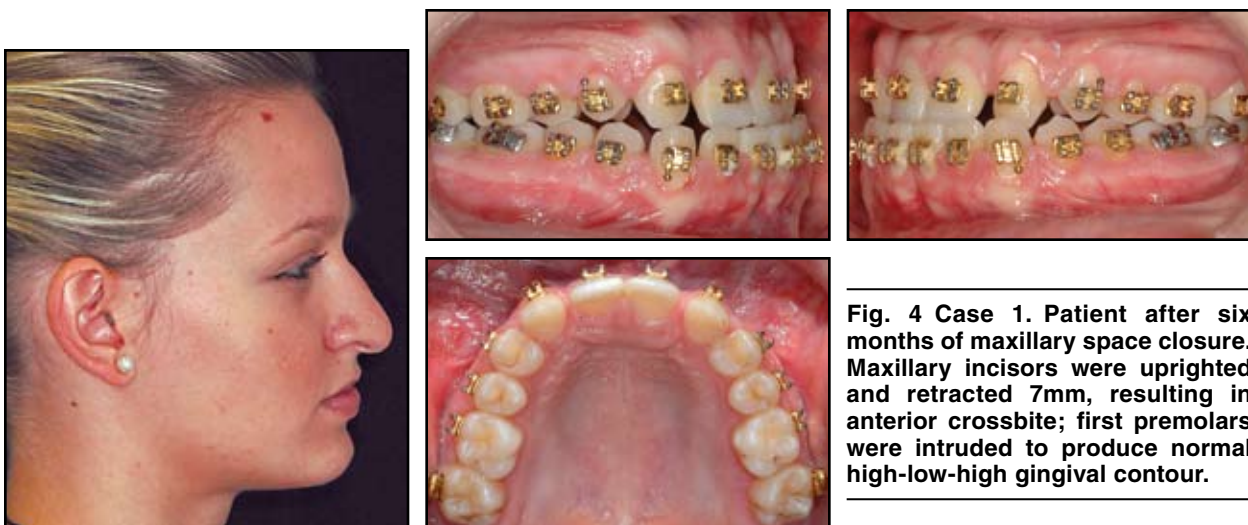


Fig. 4 Case 1. Patient after six months of maxillary space closure. Maxillary incisors were uprighted and retracted 7mm, resulting in anterior crossbite; first premolars were intruded to produce normal high-low-high gingival contour.

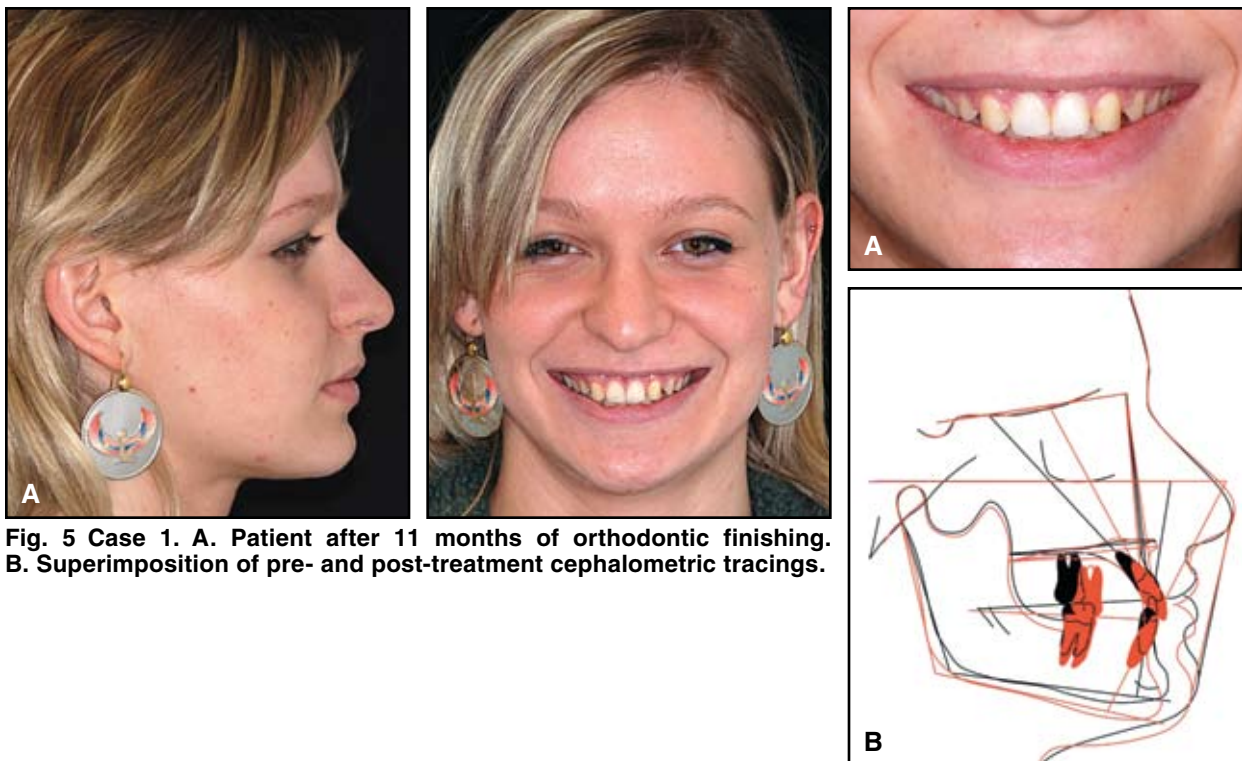


Fig. 5 Case 1. A. Patient after 11 months of orthodontic finishing. B. Superimposition of pre- and post-treatment cephalometric tracings.

control^{20,21} (Fig. 5A). The marked improvement in facial esthetics was obtained mainly by an increase in the vertical dimension at the maxillary level and concomitant mandibular rotation, rather than sagittal modifications, while the position of the upper lip in the face was unchanged (Fig. 5B).

The cosmetic phase (performed by Dr. Patrizia Lucchi, Trento, Italy) began on the day of debonding. The upper six anterior teeth were rebuilt with composite resin to obtain an ideal tooth-to-tooth and tooth-to-soft-tissue relationship (Fig. 6A). Vital bleaching was performed after the composite build-ups to match the yellowish canine to the white composite (Fig. 6B); the resin build-ups will later be replaced by porcelain laminate veneers. The final occlusion showed the first molars in a Class II relationship, with canines substituting for the missing lateral incisors and first premolars replacing the canines (Fig. 6C). The smile line and upper incisor display with the lips at rest were ideal for a woman of this age.

Retention consisted of a maxillary six-unit lingual retainer (4-3-1-1-3-4, with the distal ends bonded to the mesial occlusal surfaces of the first premolars) and a mandibular 3-3 lingual retainer.

Case 2

A 34-year-old male presented with a Class II, division 2 malocclusion in a hypodivergent skeletal pattern (Fig. 7). Both maxillary lateral incisors were missing. The upper left deciduous canine was retained, but was severely resorbed and splinted to the adjacent permanent canine and first premolar. The upper right and lower left first molars were also missing. A marked asymmetry of the dental arches and the occlusal plane made the patient's gummy smile more evident on the right side.

Considering the gummy smile and the relatively young age of the patient, we felt the placement of two implants in the esthetic zone would

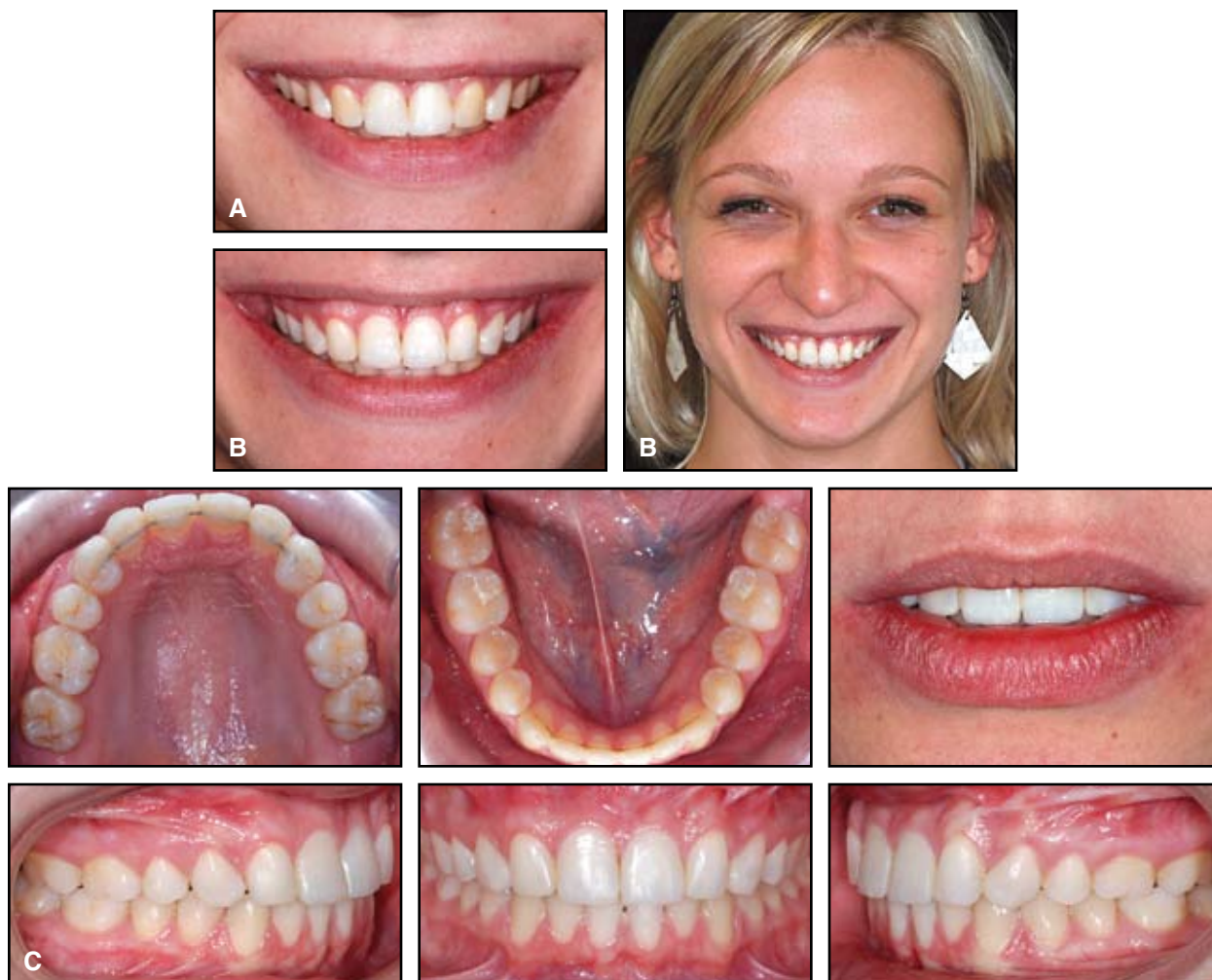

Fig. 6 Case 1. A. Composite restorations of central incisors and relocated canines and first premolars. B. After vital bleaching of relocated canines. C. Final result, with maxillary molars in Class II relationship and six anterior teeth rebuilt with composite resin to produce optimal tooth-to-tooth and tooth-to-soft-tissue relationships. Incisor display with lips at rest is ideal for young adult woman. Upper and lower six-unit retainers were bonded; resin build-ups will eventually be replaced by porcelain laminate veneers.

be an unsatisfactory long-term solution. Therefore, the treatment plan involved:

- Space closure to replace the upper left deciduous canine and correct the midline.
- Space opening between the upper right first and second premolars to allow insertion of an implant that would expedite the midline correction.
- Closure of the upper right first molar space.
- Leveling and alignment (with stripping in the

anterior region) and correction of root angulation on the lower left side, without reopening the space of the missing lower left first molar.

- Correction of the asymmetrical occlusal plane.
- Achievement of a functional, balanced occlusion with canine and incisal guidance through orthodontic treatment and restorations.
- Porcelain crown restoration over the first premolar implant.

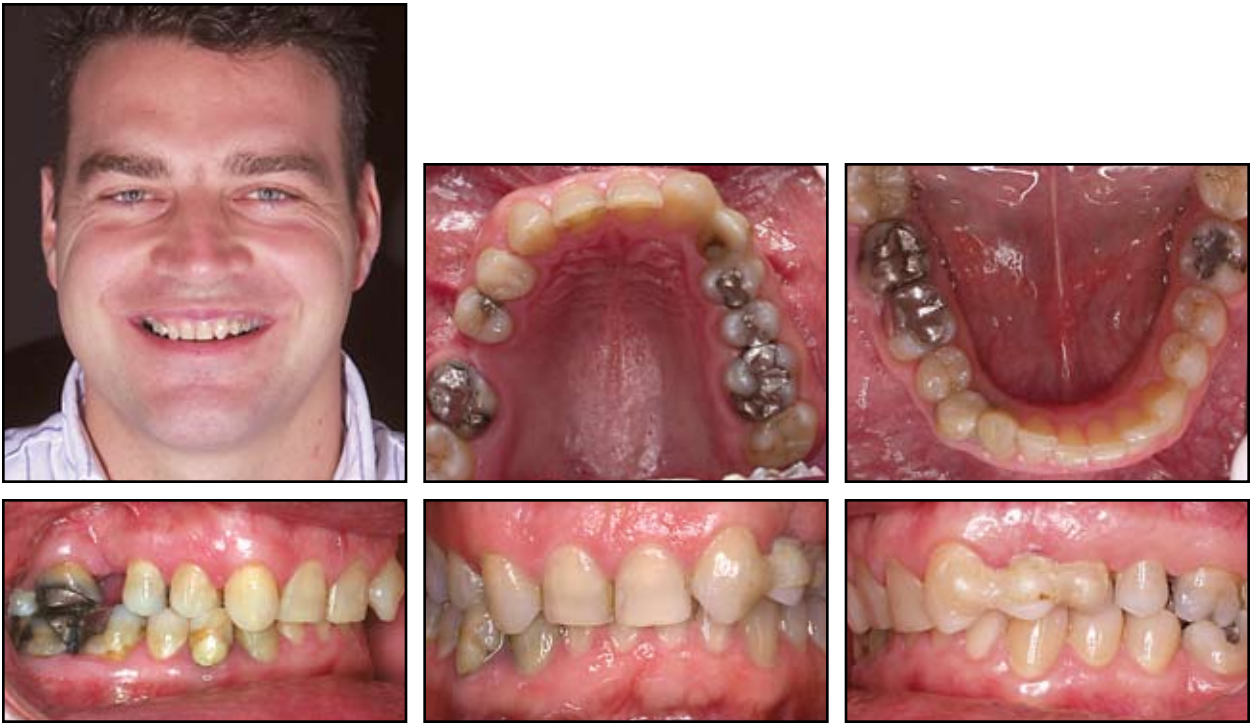

Fig. 7 Case 2. 34-year-old male patient with Class II, division 2 malocclusion, midline deviation, missing upper lateral incisors, and maxillary asymmetry due to missing upper right and lower left first molars. Retained upper left deciduous canine had been splinted to adjacent permanent canine and first premolar.

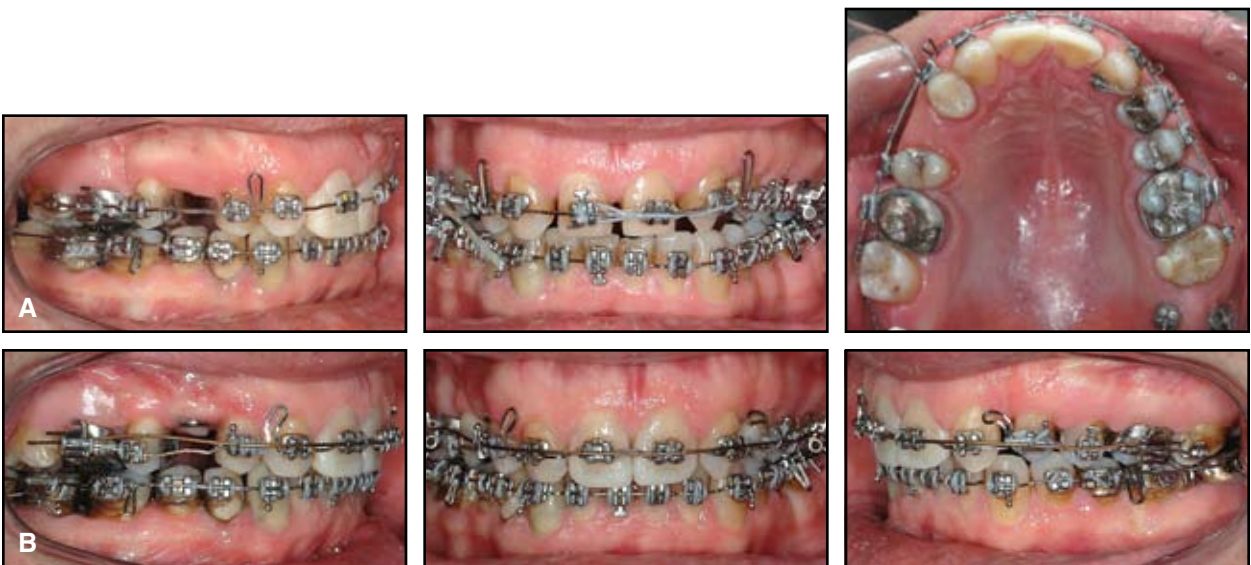
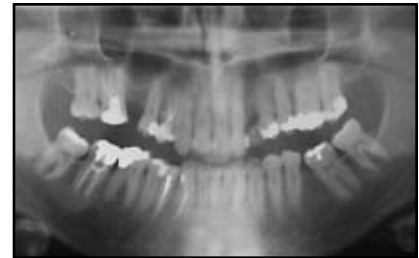
Fig. 8 Case 2. A. Patient after 18 months of treatment, showing diastemas mesial and distal to upper central incisors and space opened for implant between upper right first and second premolars. B. Upper central incisor contact points built up with composite to balance smile; dental implant inserted in space between upper right premolars. Canines were extruded, and first premolars in canine positions intruded, to produce optimal gingival margins.

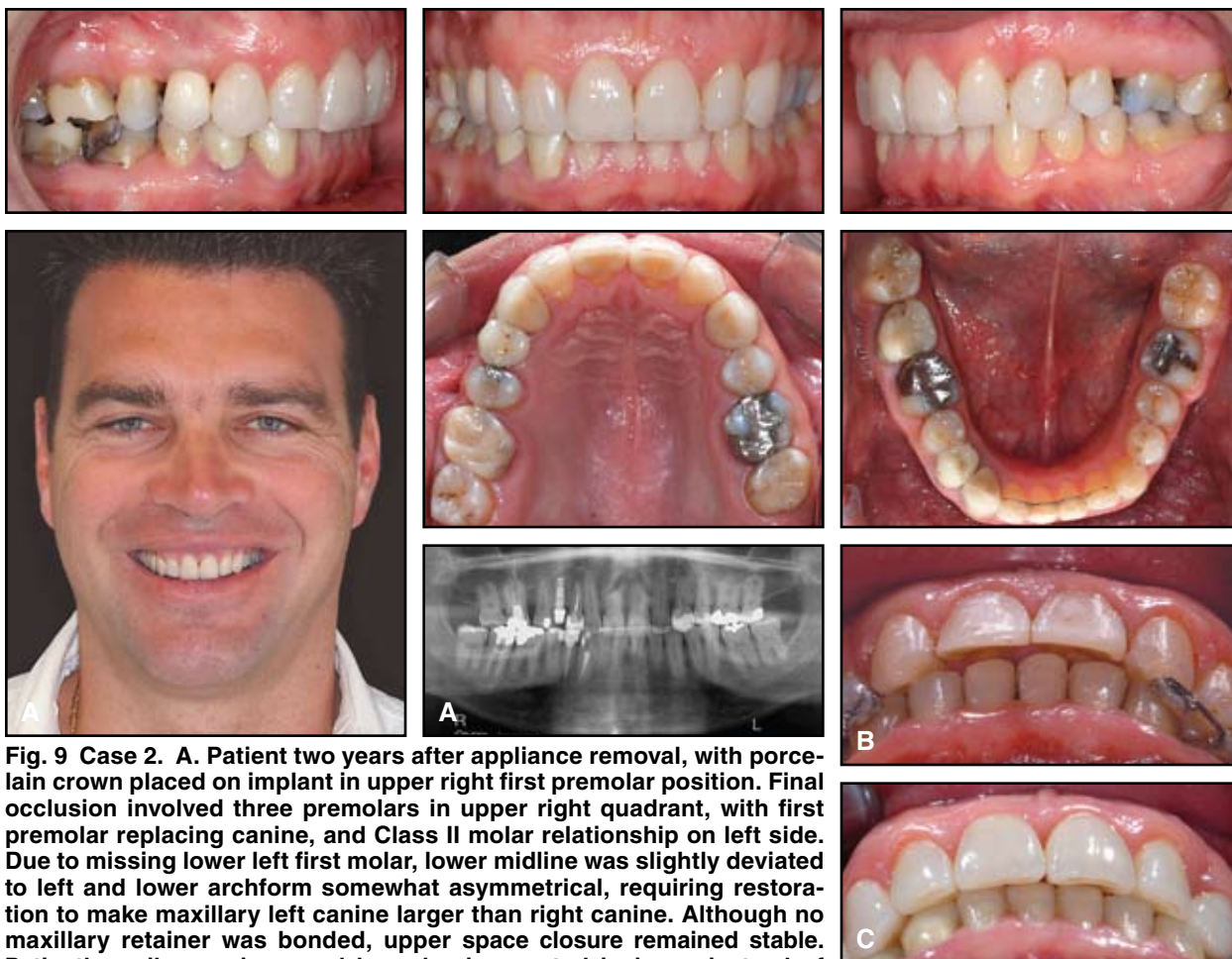


Fig. 9 Case 2. A. Patient two years after appliance removal, with porcelain crown placed on implant in upper right first premolar position. Final occlusion involved three premolars in upper right quadrant, with first premolar replacing canine, and Class II molar relationship on left side. Due to missing lower left first molar, lower midline was slightly deviated to left and lower archform somewhat asymmetrical, requiring restoration to make maxillary left canine larger than right canine. Although no maxillary retainer was bonded, upper space closure remained stable. Patient's smile was improved by enlarging central incisors, instead of grinding canines, to match "new", larger lateral incisors. **B.** 3mm overjet intentionally left after orthodontic treatment. **C.** Ideal overjet and anterior guidance achieved after restoration of small upper central incisors.

- Porcelain laminate veneers on the six anterior teeth (following composite build-ups during orthodontic treatment).

After 18 months of fixed-appliance treatment, the upper midline had been corrected, and space had been opened between the upper right premolars (Fig. 8A). Diastemas mesial and distal to the central incisors were filled with composite build-ups to make those teeth appear bigger and thus balance the smile, and an osseointegrated implant was placed by Dr. Francesca Manfrini, Riva del Garda, Italy (Fig. 8B).

Orthodontic finishing took 11 months; overall treatment time was 30 months. The final occlusion involved three maxillary premolars on the right side and the first molars in a Class II relationship on the left side, with canines substituting for the missing lateral incisors and first premolars replacing the canines on both sides (Fig. 9A). The marginal periodontal contours and smile line were optimized by the premolar intrusion, canine extru-

sion, and torque control.²⁰⁻²² The upper canines were slightly reshaped on the buccal and palatal surfaces, but were not ground or reduced in volume. Although the alignment of the six upper anterior crowns was ideal, a 3mm overjet persisted palatal to the upper central incisors (Fig. 9B); this was later filled by restorations (Fig. 9C).

The cosmetic phase, performed by Dr. Giovanni Manfrini, Riva del Garda, Italy, began during treatment with build-ups on the central incisors and continued with composite build-ups on the "new" lateral incisors and canines a few days before debonding. In the 10 months after orthodontic treatment, stabilization was achieved by occlusal equilibration. A porcelain crown was placed on the implant, while the upper six anterior teeth were restored with porcelain laminate veneers (Fig. 9A). The macroesthetic elements of the smile were in better balance than before treatment, primarily because the canines were not reduced to substitute for the lateral incisors, but the central

incisors were enlarged to match the “new” lateral incisors. This solution is often the best strategy in lateral agenesis cases, in which the central incisors tend to be small.²³

A mandibular six-unit lingual retainer was bonded; in the upper arch, an Essix* retainer was used for six months after occlusal equilibration. Two years after maxillary retention, there was no tendency for space reopening, probably because of the occlusal equilibration with no CO/CR discrepancy and with lateral working excursions of the lateral incisors, canines, and first premolars.

Discussion

These and previous case reports have demonstrated that by using a combination of carefully performed orthodontic space closure and cosmetic build-ups of several teeth with either composite resin or porcelain laminate veneers, it is possible to treat patients with one or both missing maxillary lateral incisors and a coexisting malocclusion to a result that provides the look of a healthy, natural dentition.^{20,21}

A major advantage of such an approach is the permanence of the finished result. The alveolar bone height is maintained by early mesial movement of the canine, and the need for removable or resin-bonded retainers until the implant insertion is avoided. At the end of orthodontic treatment, porcelain veneers can be placed directly on any of the anterior teeth, because the two common reasons for postponing permanent restorations in young and adolescent patients—risk of pulp perforation and exposure of gingival crown margins during tooth eruption—are not contraindications for the minimally invasive preparations with enamel-bonded porcelain.^{24,25} The tendency of the spaces to reopen after treatment can be overcome with properly finished occlusal contacts and long-term retention. A bonded retainer should be supplemented with a removable plate to be worn continuously for six months and then at night. No apparent side effects were noticed from this regimen in a 10-year follow-up study.²⁶

With the space-closure alternative, the healthy gingival tissues and intact interdental gingival papillae will mature in synchrony with the patient’s own teeth, so that long-term modifications will appear naturally (Fig. 2). This is in contrast to long-term experiences with single-implant crowns in the esthetic zone.^{9,10,13} In an award-winning article describing 10-year follow-ups of oral implants, Thilander and colleagues found increasing degrees of infraocclusion even after completion of growth, and significant marginal bone loss at tooth surfaces adjacent to the implants.⁹ Marked infraocclusion of single-implant crowns in mature adults was also reported by Bernard and colleagues¹⁰ and by Jemt.¹³ Our conclusion is that lateral incisor agenesis in patients with gummy smiles should be treated with space closure. If the treatment plan must include space reopening, it is preferable to open the spaces posteriorly and insert implants in the premolar areas¹¹ (Figs. 7,8).

Our experience with currently available materials for composite build-ups has been unsatisfactory, since such restorations need frequent maintenance and renewal. Except for composite “corners” on canines in lateral incisor positions, we therefore prefer to use the more durable porcelain veneers.^{24,25} If desired, these can be made after a retention period and after functional occlusal adjustments by selective grinding. Porcelain veneers on the canines and first premolars,^{20,21} as well as on the central incisors if these need to be widened or elongated,^{16,23} are more expensive for the patient than grinding and build-ups, but their cost compares favorably with that of restorations on single-tooth implants. Long-term maintenance of composite resin build-ups can also be expensive. The porcelain veneers have shown excellent long-term durability and esthetics, even when the gingival margin retracts with time. Light reflection appears normal, in contrast to ceramic crowns and porcelain-fused-to-gold teeth, where the shadowing effect of the incoming light results in a dark background.²⁴

Agenesis of lateral incisors in Class III malocclusions, especially with narrow maxillae and pronounced spacing, has traditionally been regarded as an undebatable indication for space reopen-

*Dentsply Raintree Essix, 6448 Parkland Drive, Sarasota, FL 34243; www.essix.com.

ing and prosthetic rehabilitation. It is held that the reopening of spaces facilitates expansion of the maxillary arch and provides dentoalveolar compensation, significantly improving the profile. The Class III case shown here (Figs. 3,4), like similar cases described previously,^{21,27} demonstrates that space closure can be a valid alternative. The changes in the face and profile are more correlated to modifications made in the vertical dimension than to sagittal changes at the incisor level. It is remarkable that in the patient shown here, even after a 7mm retraction of the upper incisors with a resulting anterior crossbite, there was no noticeable profile change. Recent developments in mini-screws may facilitate anchorage in such cases. Class III patients with missing lateral incisors are obviously difficult to treat, and good compliance is mandatory, but long-term stability can still be achieved without negative side effects on the face and profile.

REFERENCES

1. Tuverson, D.L.: Orthodontic treatment using canines in place of missing maxillary lateral incisors, *Am. J. Orthod.* 58:109-127, 1970.
2. Armbruster, P.C.; Gardiner, D.M.; Whitley, J.B. Jr.; and Flerra, J.: The congenitally missing maxillary lateral incisor, Part 1: Esthetic judgment of treatment options; Part 2: Assessing dentists' preferences for treatment, *World J. Orthod.* 6:369-381, 2005.
3. Kinzer, G.A. and Kokich, V.O. Jr.: Managing congenitally missing lateral incisors, Part III: Single-tooth implants, *J. Esth. Restor. Dent.* 17:202-210, 2005.
4. Spear, F.M.; Mathews, D.M.; and Kokich, V.G.: Interdisciplinary management of single-tooth implants, *Semin. Orthod.* 3:45-72, 1997.
5. Kokich, V.G.: Maxillary lateral incisor implants: Planning with the aid of orthodontics, *J. Oral Maxillofac. Surg.* 62:48-56, 2004.
6. Kinzer, G.A. and Kokich, V.O. Jr.: Managing congenitally missing lateral incisors, Part II: Tooth-supported restorations, *J. Esth. Restor. Dent.* 17:76-84, 2005.
7. Arnoux, J.P.; Weisgold, A.S.; and Lu, J.: Single-tooth anterior implant: A word of caution, Part II, *J. Esth. Dent.* 9:285-294, 1997.
8. Jung, R.E.; Pjetursson, B.E.; Glauser, R.; Zembic, A.; Zwahlen, M.; and Lang, N.P.: A systematic review of the 5-year survival and complication rates of implant-supported single crowns, *Clin. Oral Impl. Res.* 19:119-130, 2008.
9. Thilander, B.; Odman, J.; and Lekholm, U.: Orthodontic aspects of the use of oral implants in adolescents: A 10-year follow-up study, *Eur. J. Orthod.* 23:715-731, 2001.
10. Bernard, J.P.; Schatz, J.P.; Christou, P.; Belser, U.; and Kiliaridis, S.: Long-term vertical changes of the anterior maxillary teeth adjacent to single implants in young and mature adults: A retrospective study, *J. Clin. Periodontol.* 31:1024-1028, 2004.
11. Zachrisson, B.U.: Single implant-supported crowns for the anterior maxilla: Potential esthetic long-term (> 5 years) problems, *World J. Orthod.* 7:306-312, 2006.
12. Dueled, E.; Gotfredsen, K.; Damsgaard, M.T.; and Hede, B.: Professional and patient-based evaluation of oral rehabilitation in patients with tooth agenesis, *Clin. Oral Impl. Res.* 20:729-736, 2009.
13. Jemt, T.: Measurements of tooth movements in relation to single-implant restorations during 16 years: A case report, *Clin. Impl. Dent. Related Res.* 7:200-208, 2005.
14. Jemt, T.; Ahlberg, G.; Henriksson, K.; and Bondevik, O.: Changes of anterior clinical crown height in patients provided with single-implant restorations after more than 15 years of follow-up, *Int. J. Prosthodont.* 19:455-461, 2006.
15. Jemt, T.: Single implants in the anterior maxilla after 15 years of follow-up: Comparison with central implants in the edentulous maxilla, *Int. J. Prosthodont.* 21:400-08, 2008.
16. Björk, A. and Palling, M.: Adolescent age changes in sagittal jaw relation, alveolar prognathia, and incisal inclination, *Acta Odont. Scand.* 12:201-232, 1955.
17. Bondevik, O.: Does pregnancy or use of contraceptives influence adult facial changes? *J. Orofac. Orthop.* 71:32-39, 2010.
18. Chang, M.; Wennström, J.L.; Odman, P.; and Andersson, B.: Implant supported single-tooth replacements compared to contralateral natural teeth: Crown and soft tissue dimensions, *Clin. Oral Impl. Res.* 10:185-194, 1999.
19. Tuverson, D.L.: Close space to treat missing lateral incisors, *Am. J. Orthod.* 125(5):17A, 2004.
20. Rosa, M. and Zachrisson, B.U.: Integrating esthetic dentistry and space closure in patients with missing maxillary lateral incisors, *J. Clin. Orthod.* 35:221-234, 2001.
21. Rosa, M. and Zachrisson, B.U.: Integrating esthetic dentistry and space closure in patients with missing maxillary lateral incisors: Further improvements, *J. Clin. Orthod.* 41:563-573, 2007.
22. Zachrisson, B.U.: Buccal uprighting of canines and premolars for improved smile esthetics and stability, *World J. Orthod.* 7:406-412, 2006.
23. Olivadoti, A.; Doldo, T.; and Treccani, M.: Morpho-dimensional analysis of the maxillary central incisor clinical crown in cases of congenitally missing upper lateral incisors, *Prog. Orthod.* 10:12-19, 2009.
24. Zachrisson, B.U. and Toreskog, S.: Esthetic considerations in restoring the traumatized dentition: A biologic approach, in *Textbook and Color Atlas of Traumatic Injuries to the Teeth*, 4th ed., ed. J.O. Andreasen, F.M. Andreasen, and L. Andersson, Blackwell Munksgaard, Oxford, England, 2007, pp. 798-813.
25. Zachrisson, B.U. and Toreskog, S.: Missing maxillary central incisors: Interdisciplinary approach with orthodontic space closure, autotransplantation of premolars, and single-tooth implants, in *The Art of the Smile*, ed. R. Romano, Quintessence Publishing, London, 2005, pp. 142-166.
26. Thordarson, A.; Zachrisson, B.U.; and Mjör, I.A.: Remodeling of canines to the shape of lateral incisors by grinding: A long-term clinical and radiographic evaluation, *Am. J. Orthod.* 100:123-132, 1991.
27. Tabuchi, M.; Fukuoka, H.; Miyazawa, K.; and Goto, S.: Skeletal Class III malocclusion with unilateral congenitally missing maxillary incisor treated by maxillary protractor and edgewise appliances, *Angle Orthod.* 80:405-418, 2010.